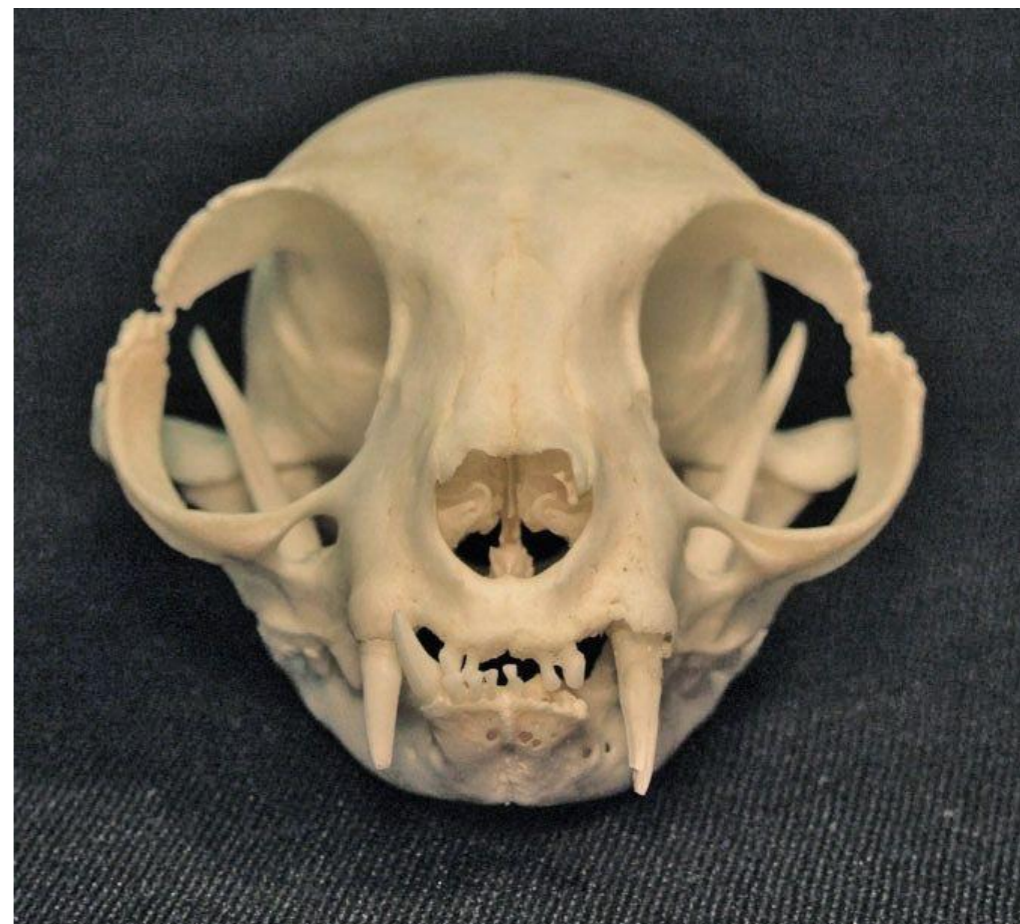
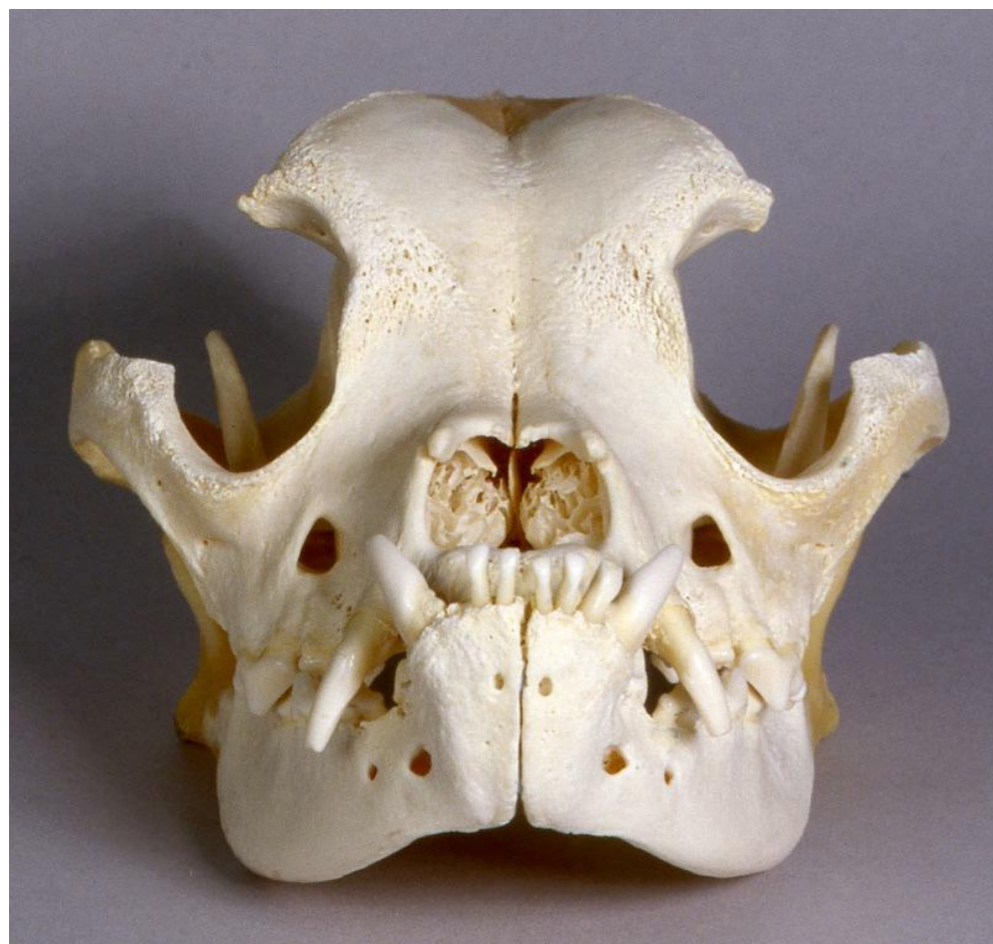
**Stomatologie koček a psů**  
**Onemocnění parodontu: krok za**  
**krokem interaktivní postup**

**Stomatology of cats and dogs**  
**Interactive step by step approach to periodontal diseases.**

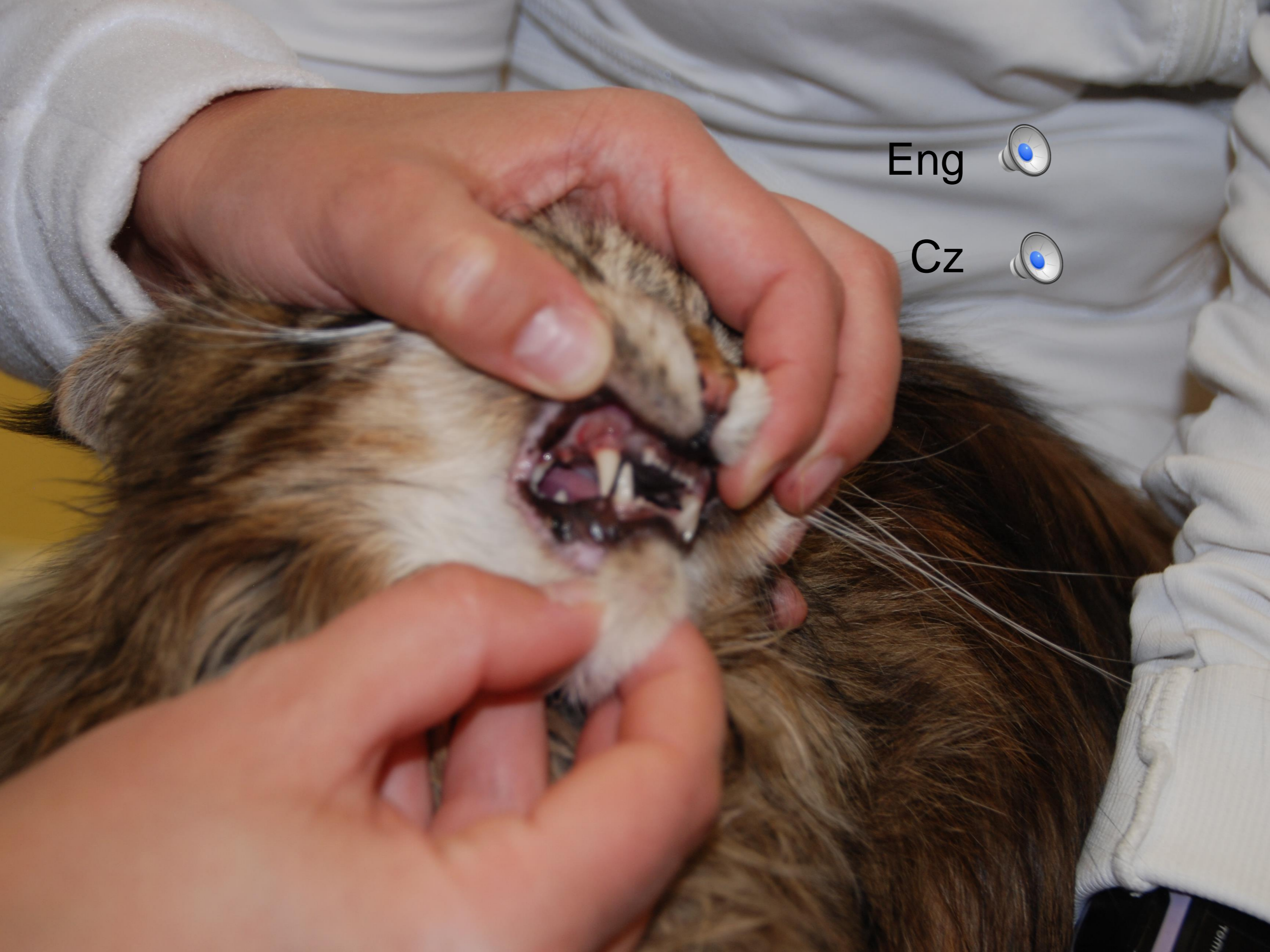

- *Prevention is the best cure*
- *Periodontal diseases PDI 1-4*
- *Teeth and root fx.*
- *ONF*
- *Stomatitis*
- *ORL*
- *Hyperplastic gingiva*
- *Oncological surgery*
- *Trauma*

Prevention is the best cure

Eng



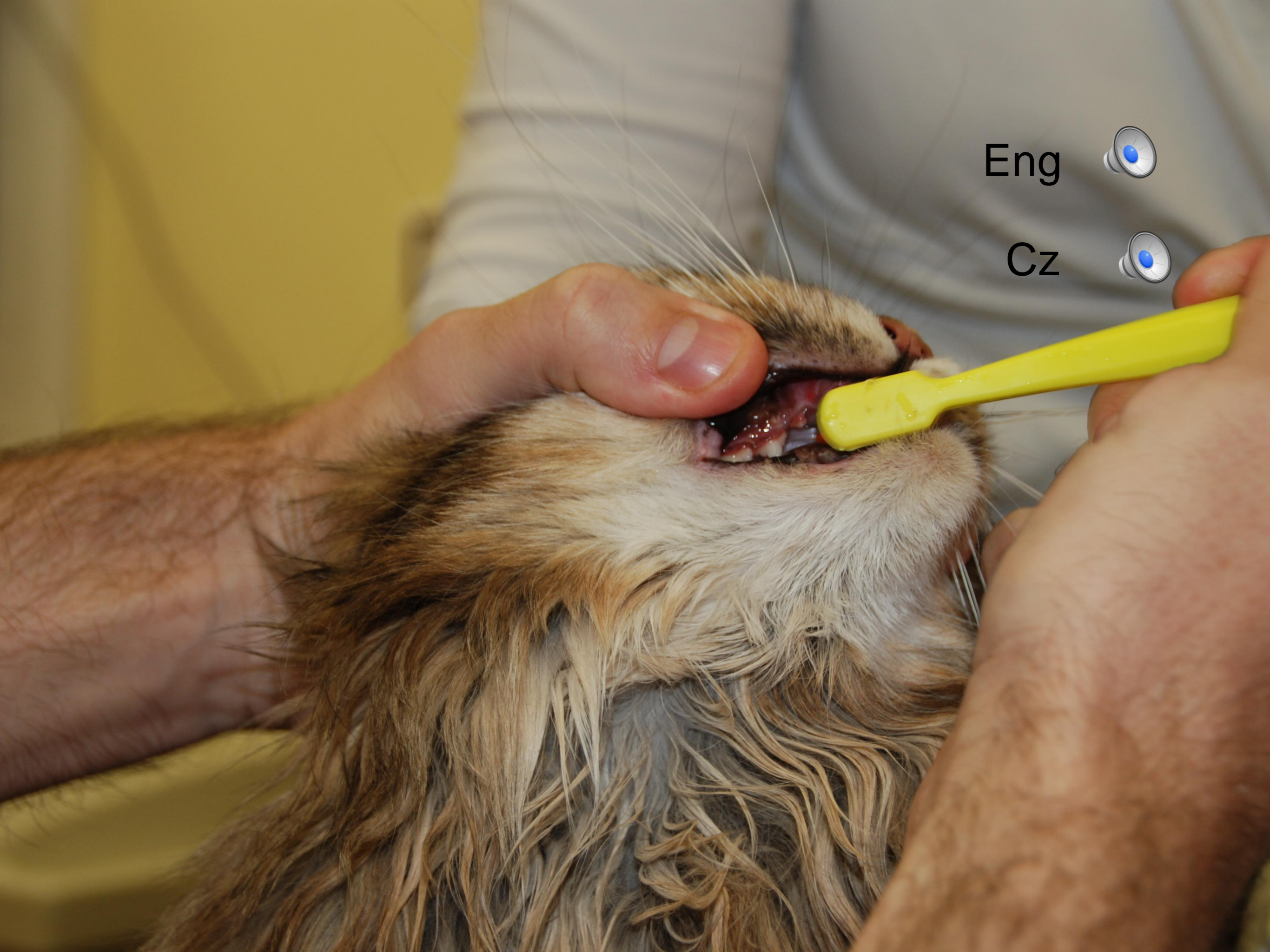


Eng



Cz





Eng



Cz

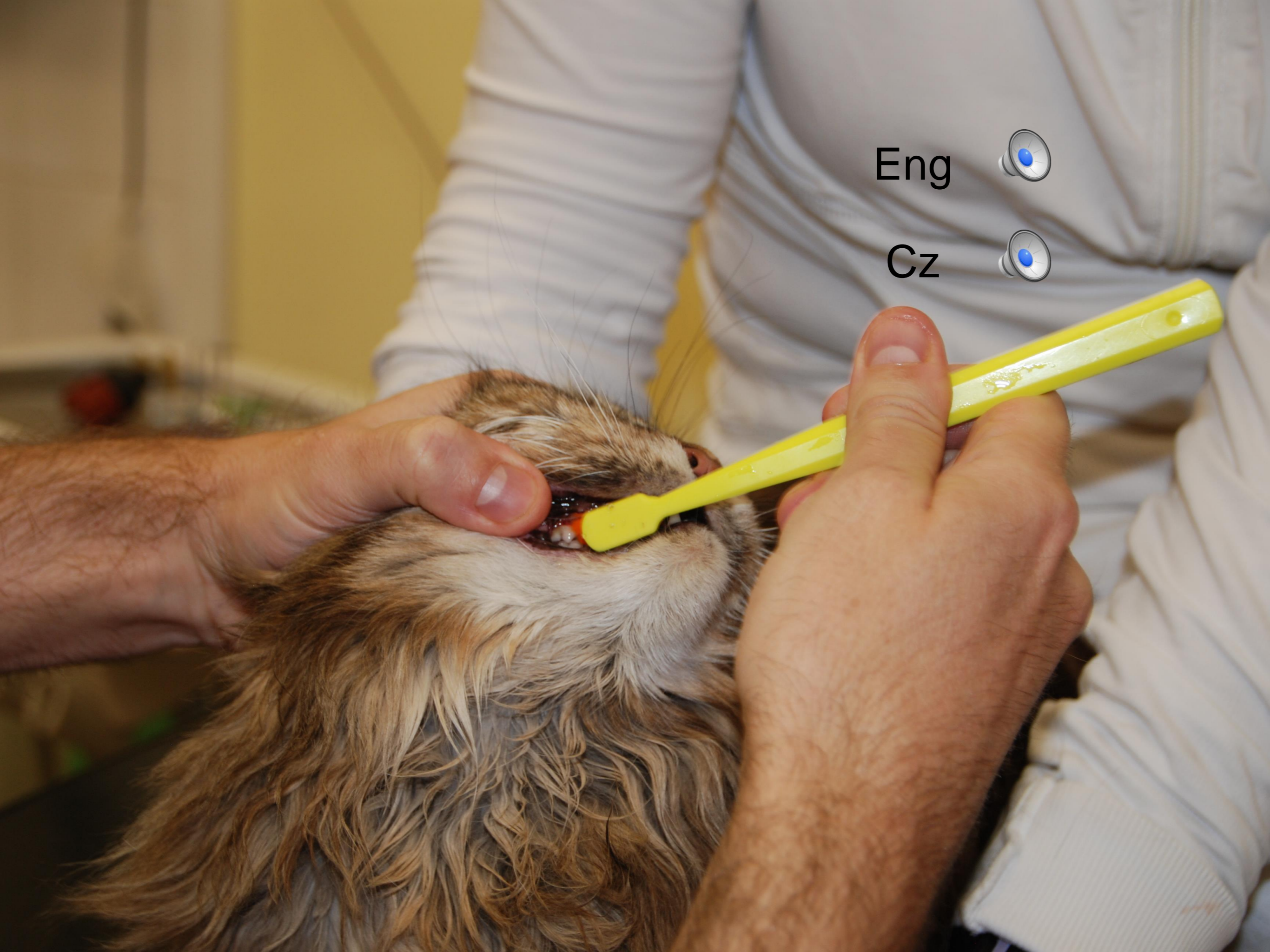

Eng



Cz



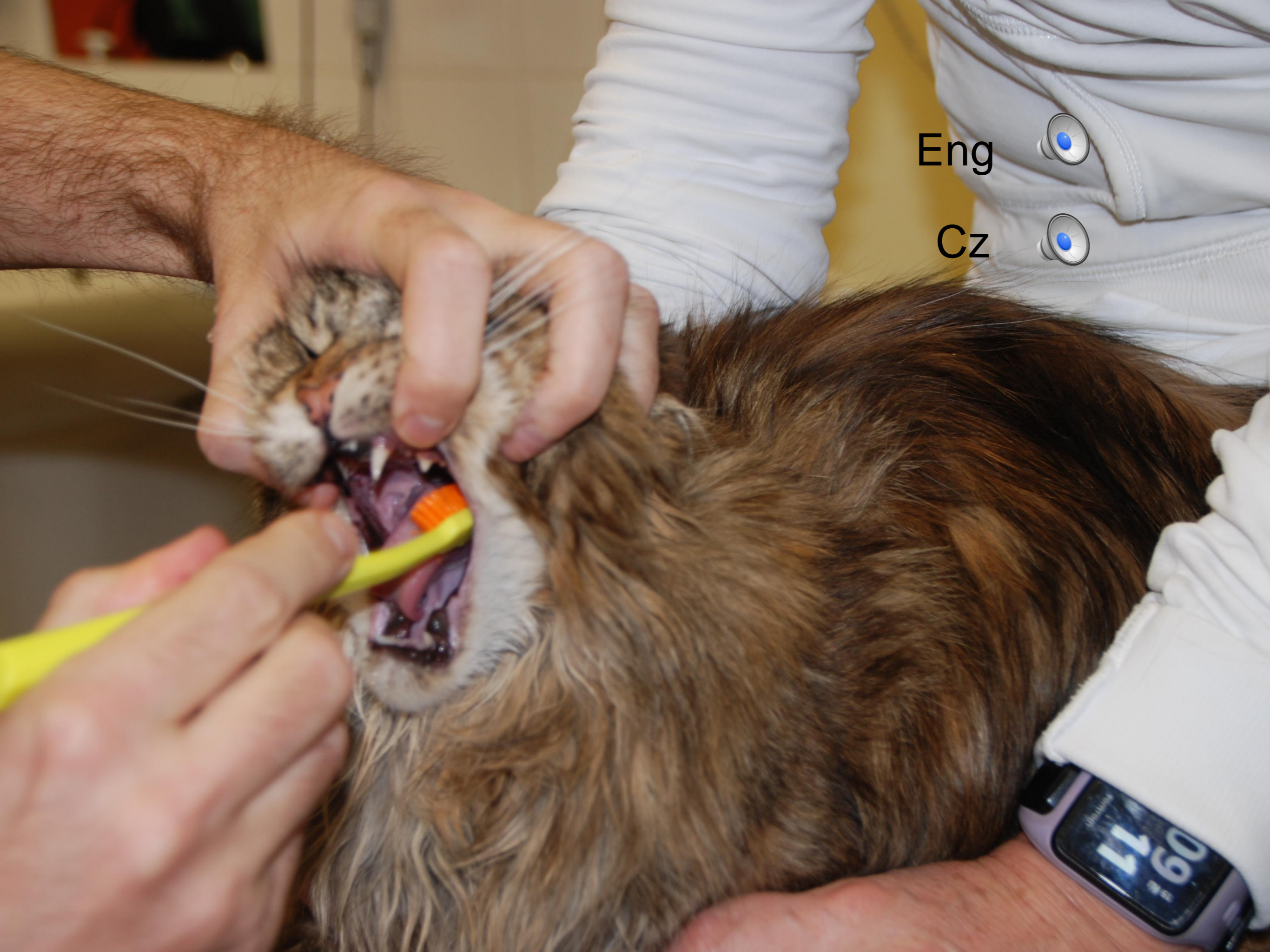


Eng



Cz





Eng



Cz





PDI

Eng 

Cz 

PDI 1

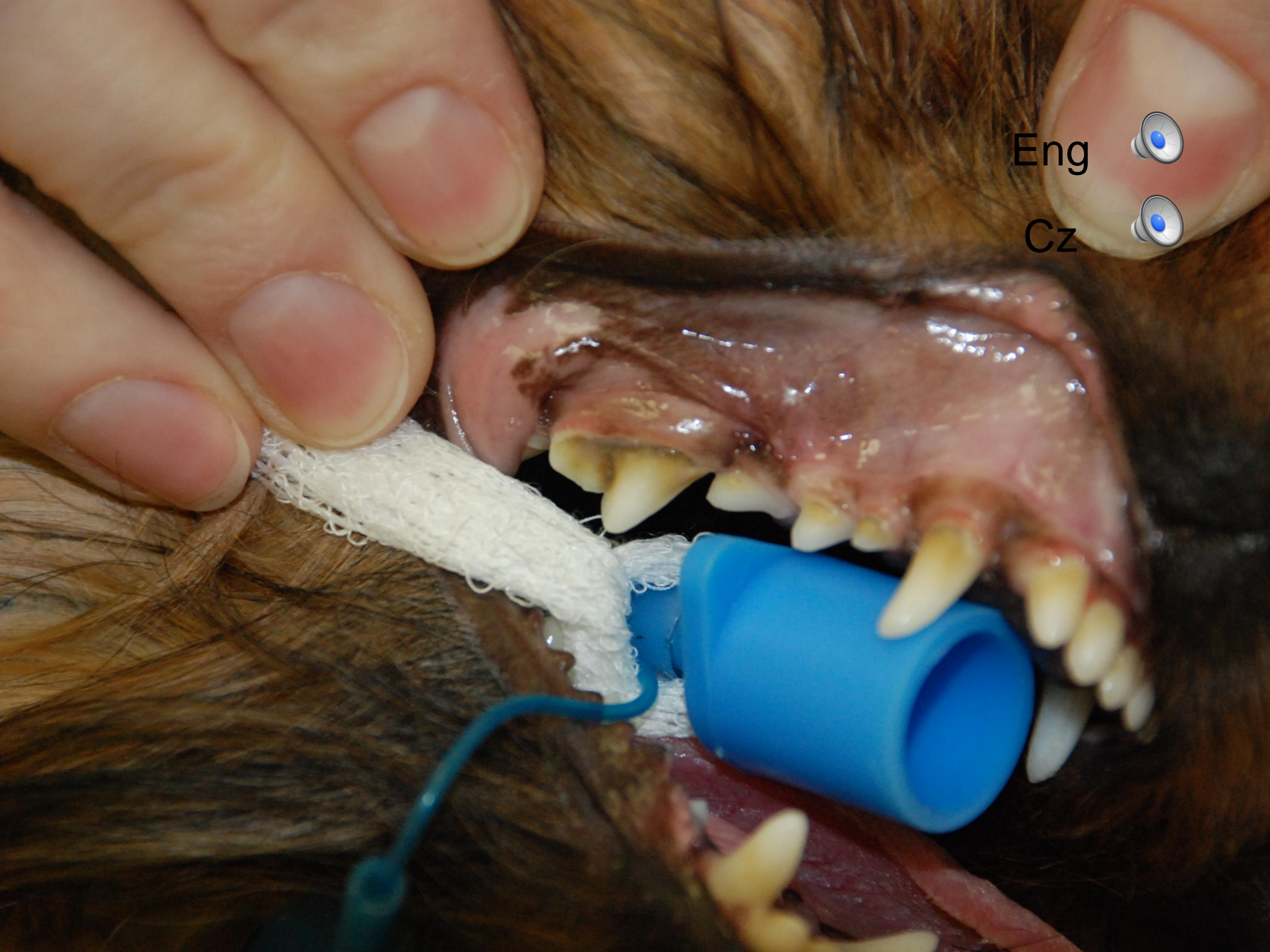Eng 

Cz 

Eng

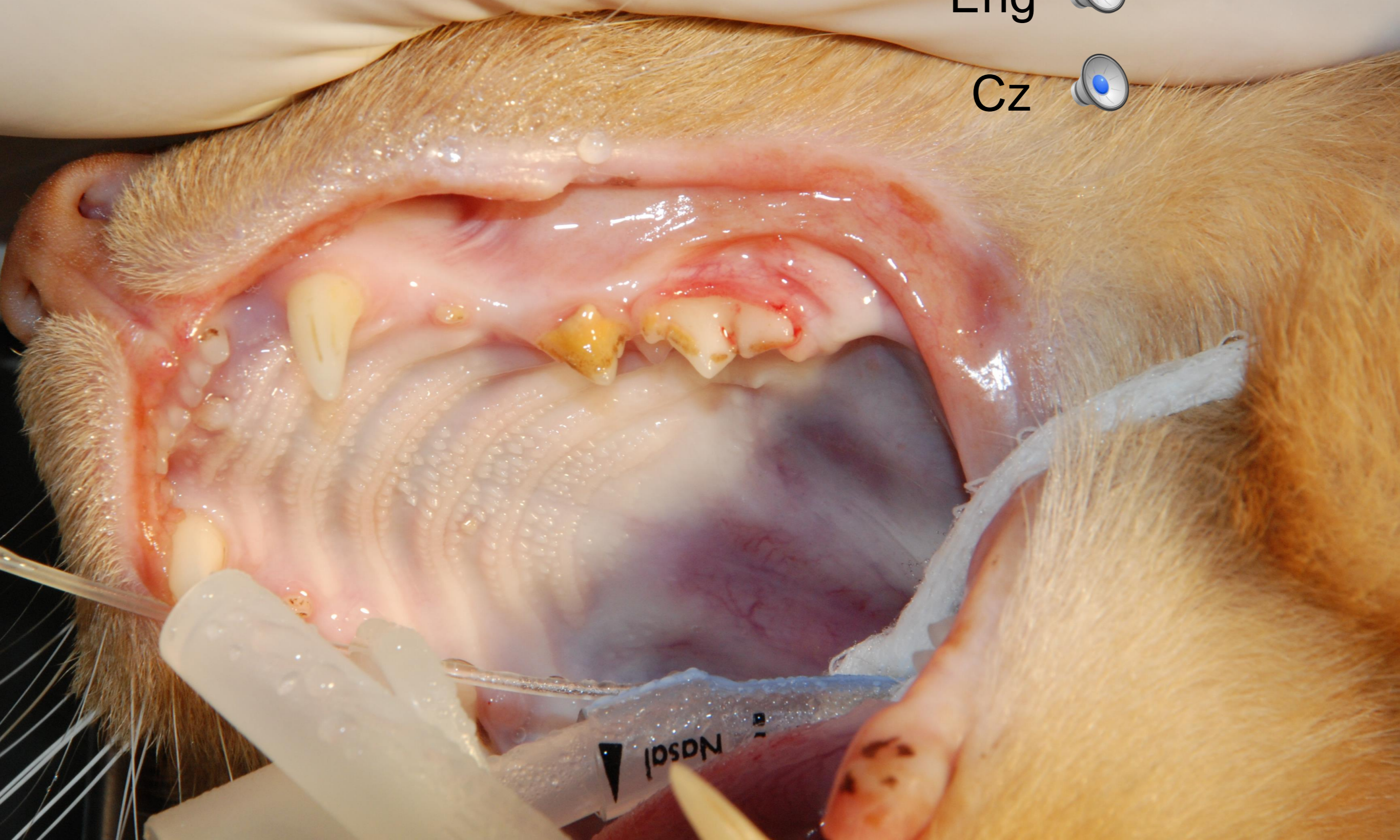

Cz



Eng 

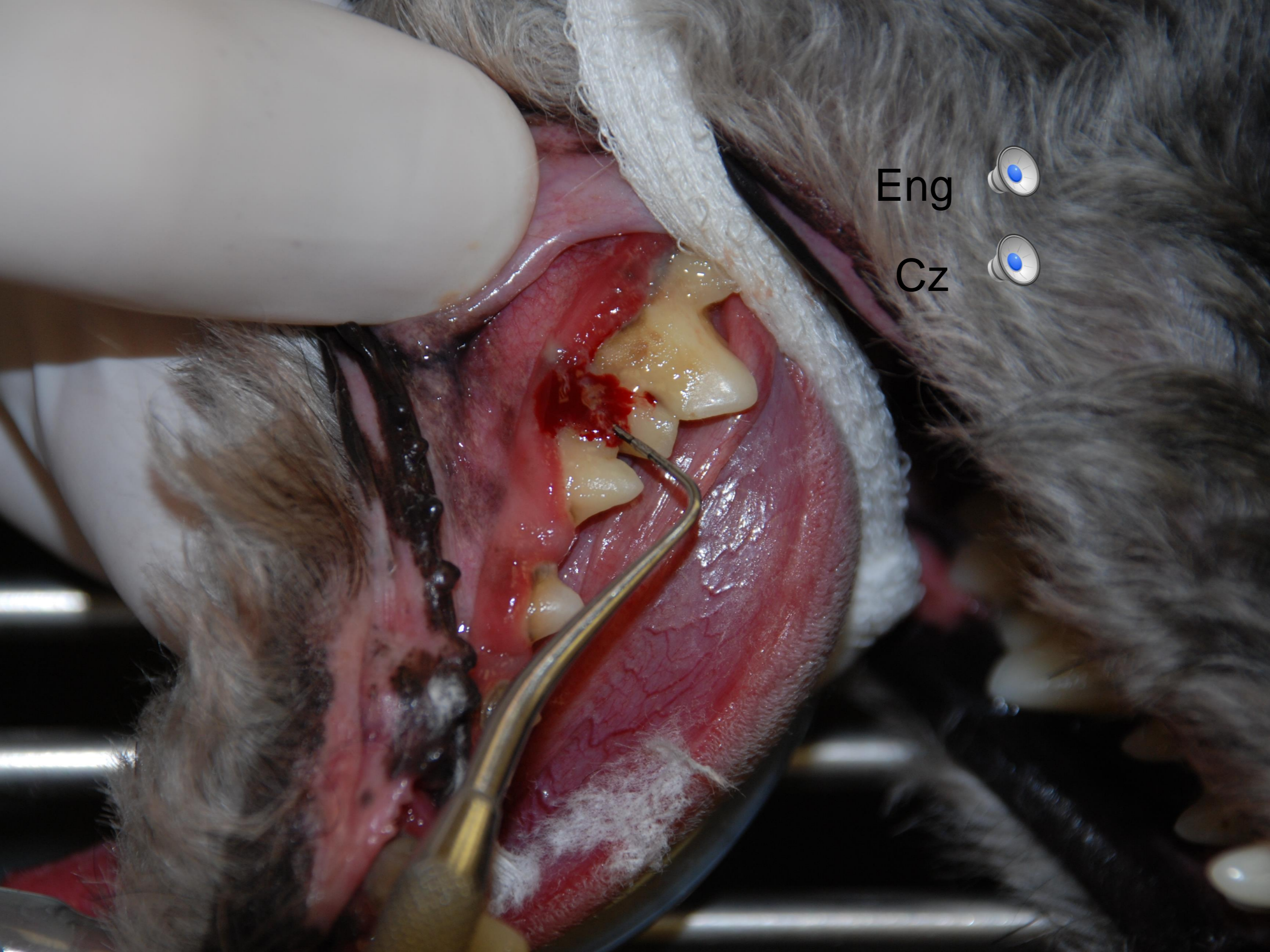Cz 



# PDI 2-3

Eng 

Cz 



Eng



Cz



Eng



Cz



Eng



Cz





PDI 4

Eng 

Cz 

Eng

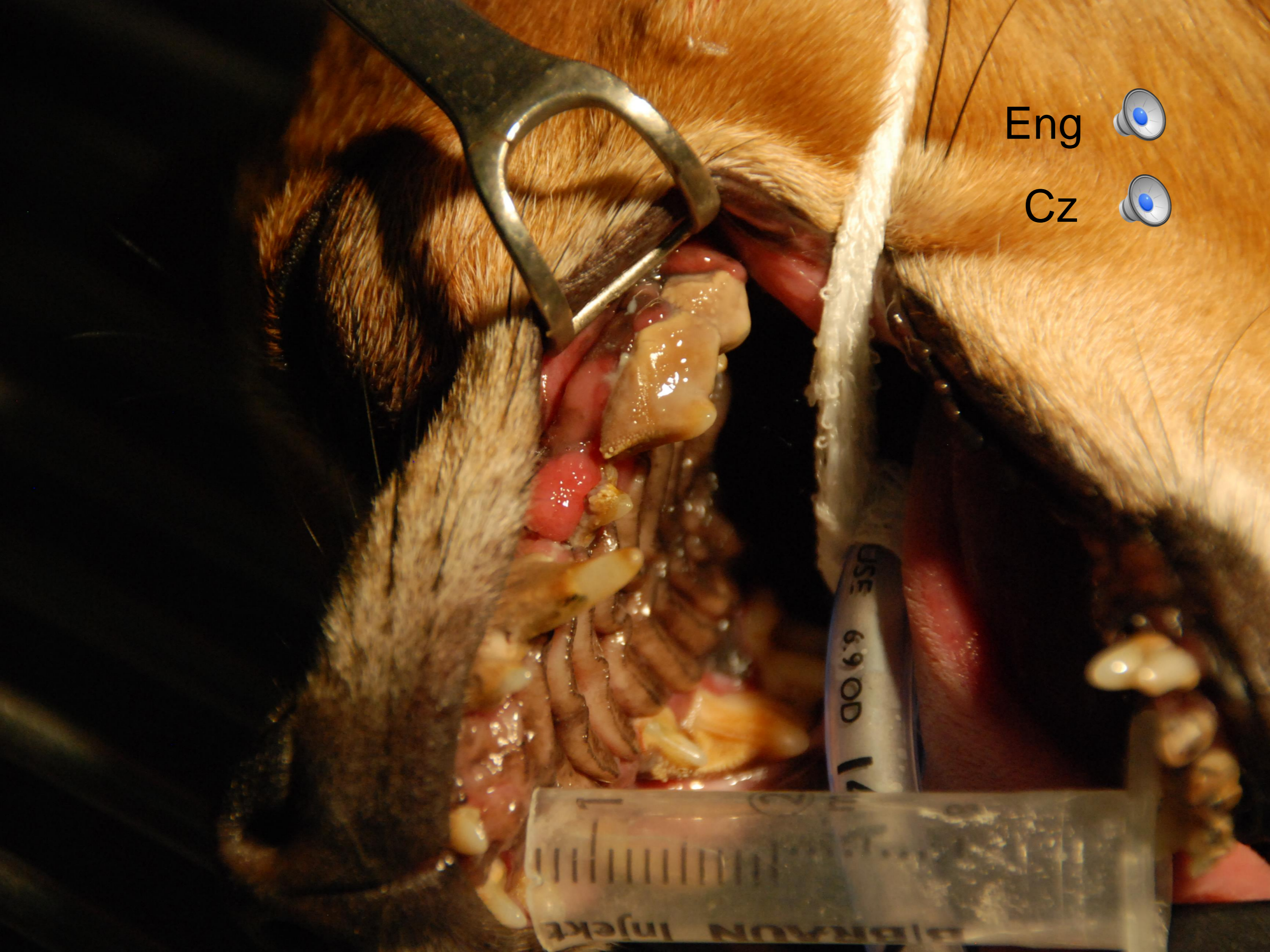


Cz



Eng 

Cz 

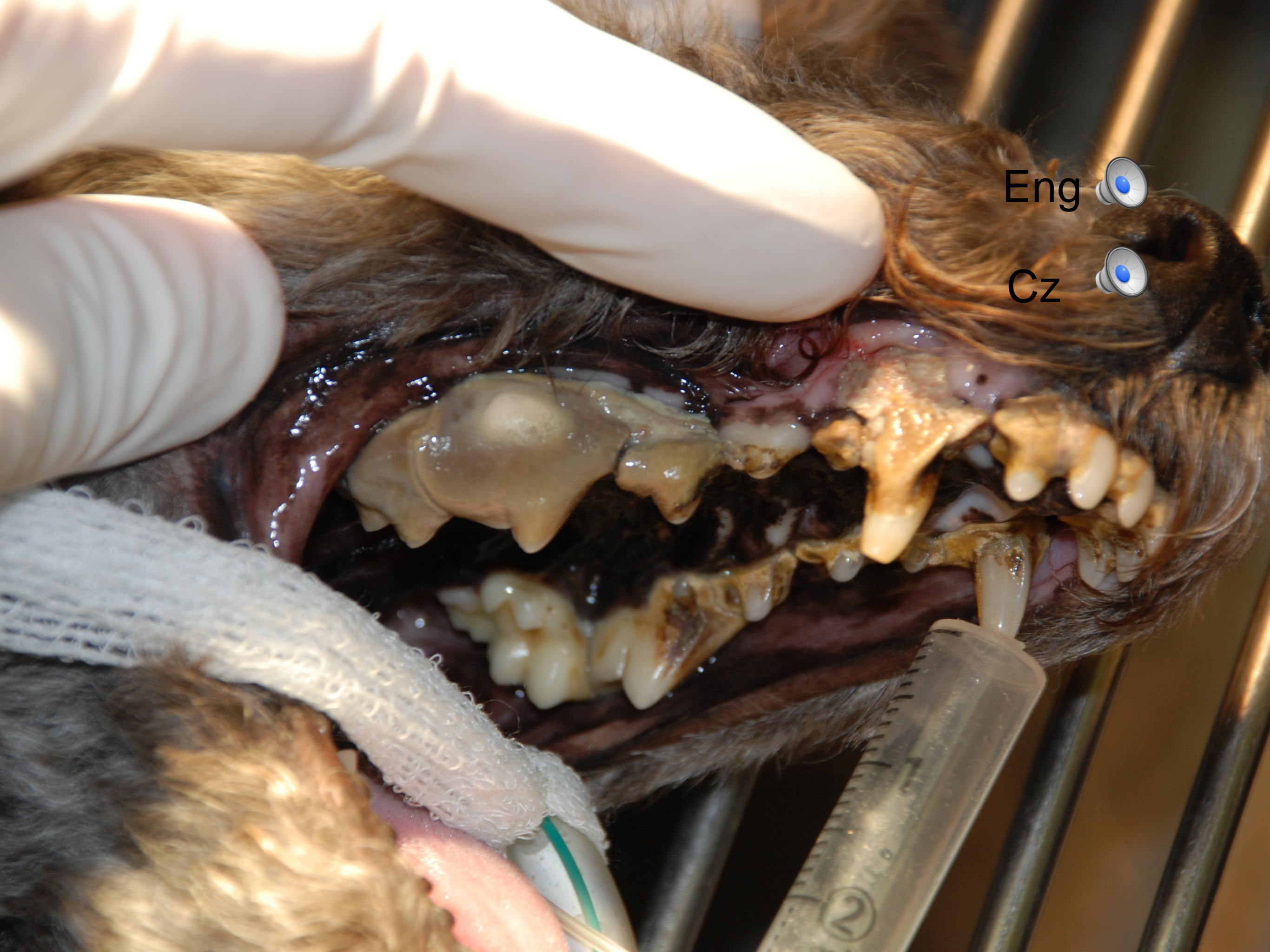

Eng



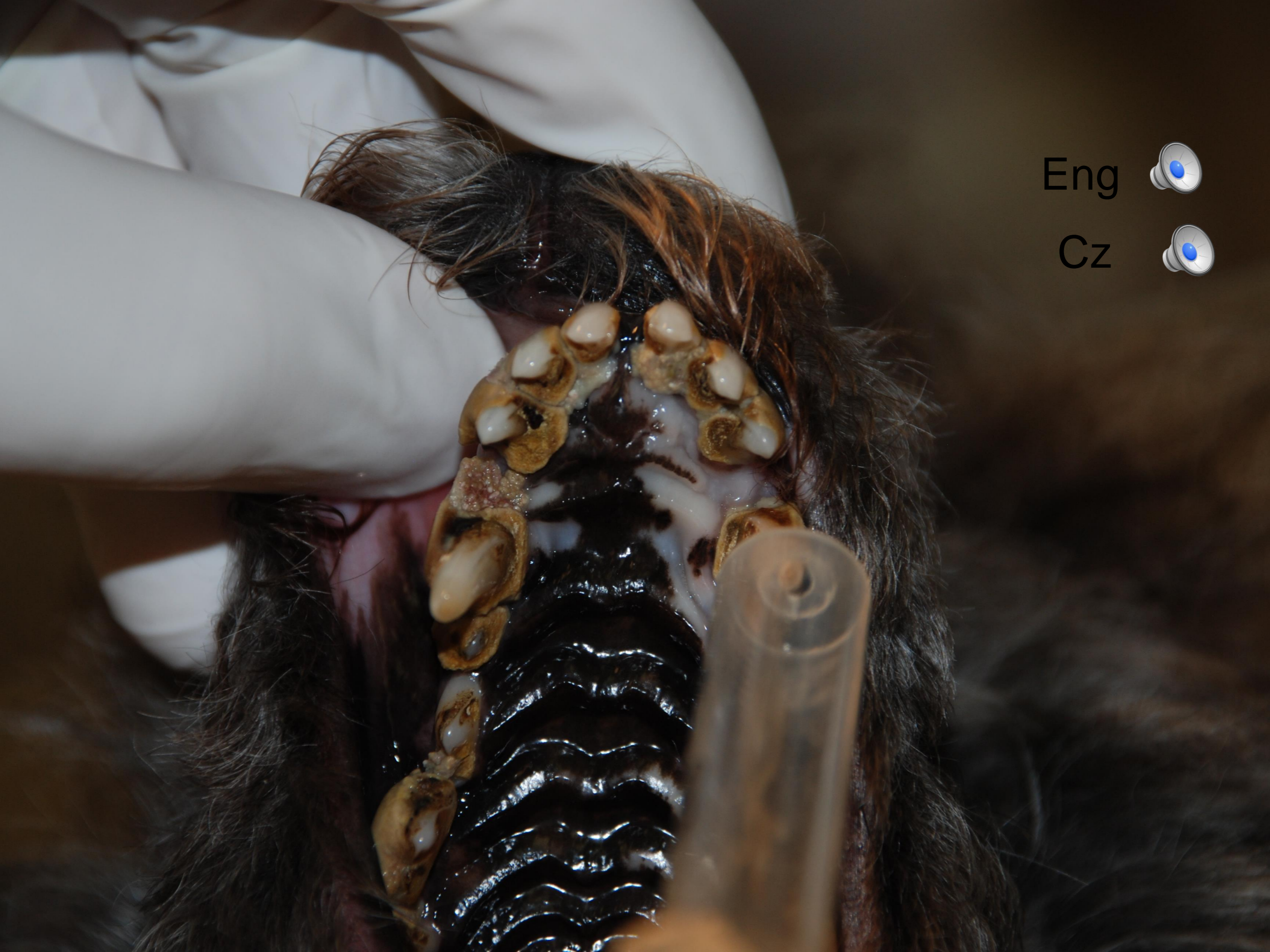Cz





Eng 

Cz 

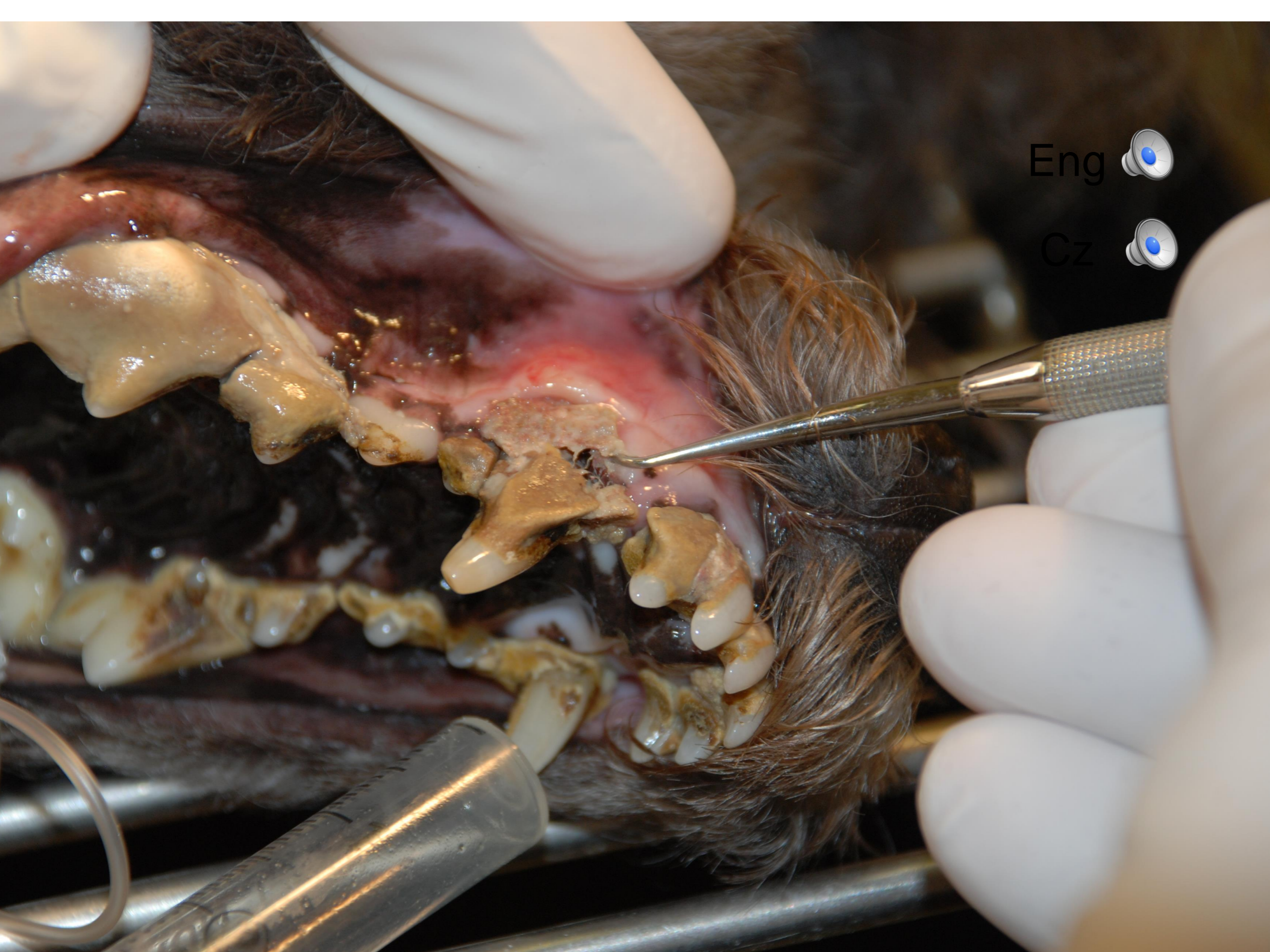

Eng



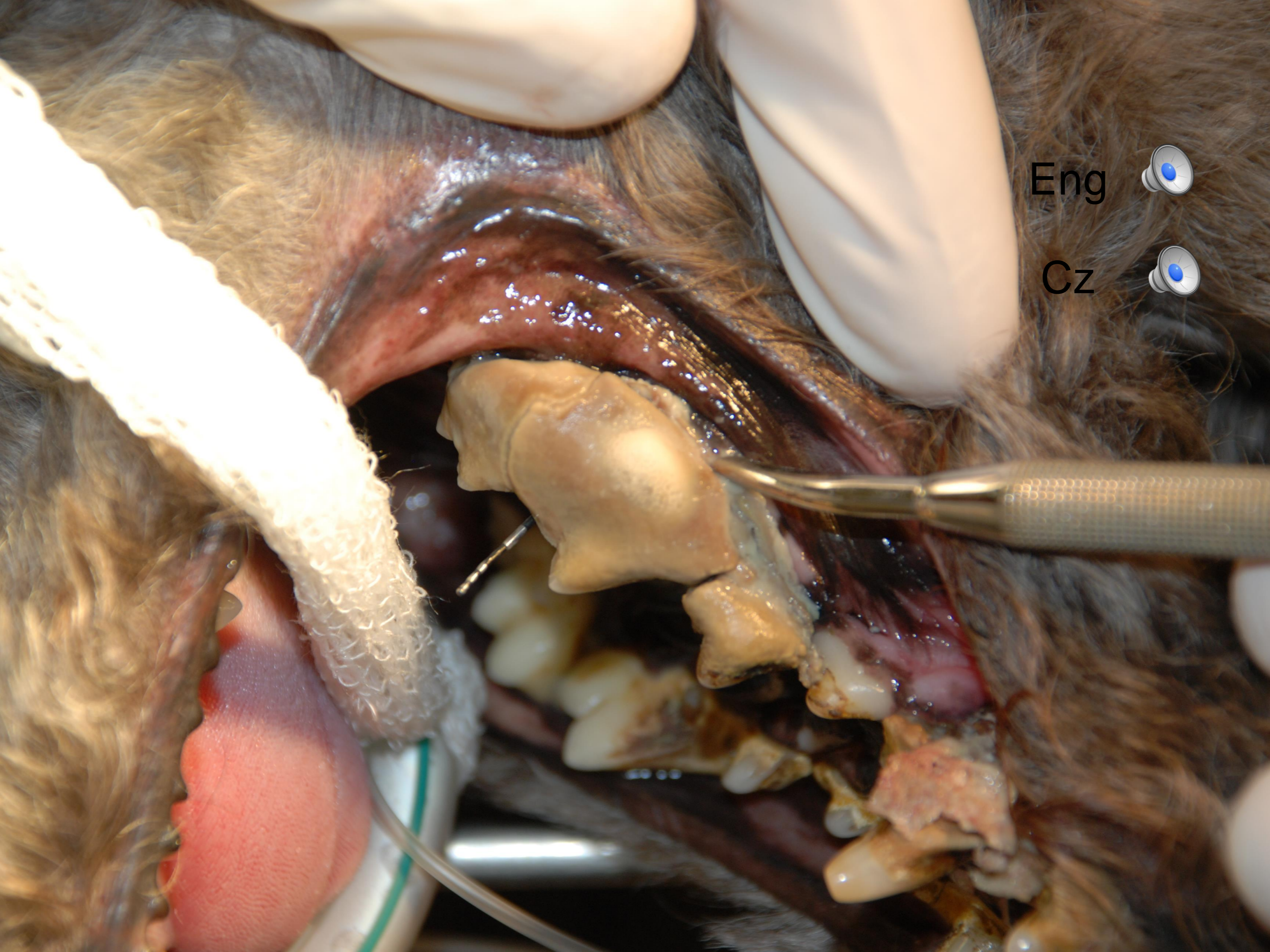
Cz





Eng 

Cz 



Eng



Cz

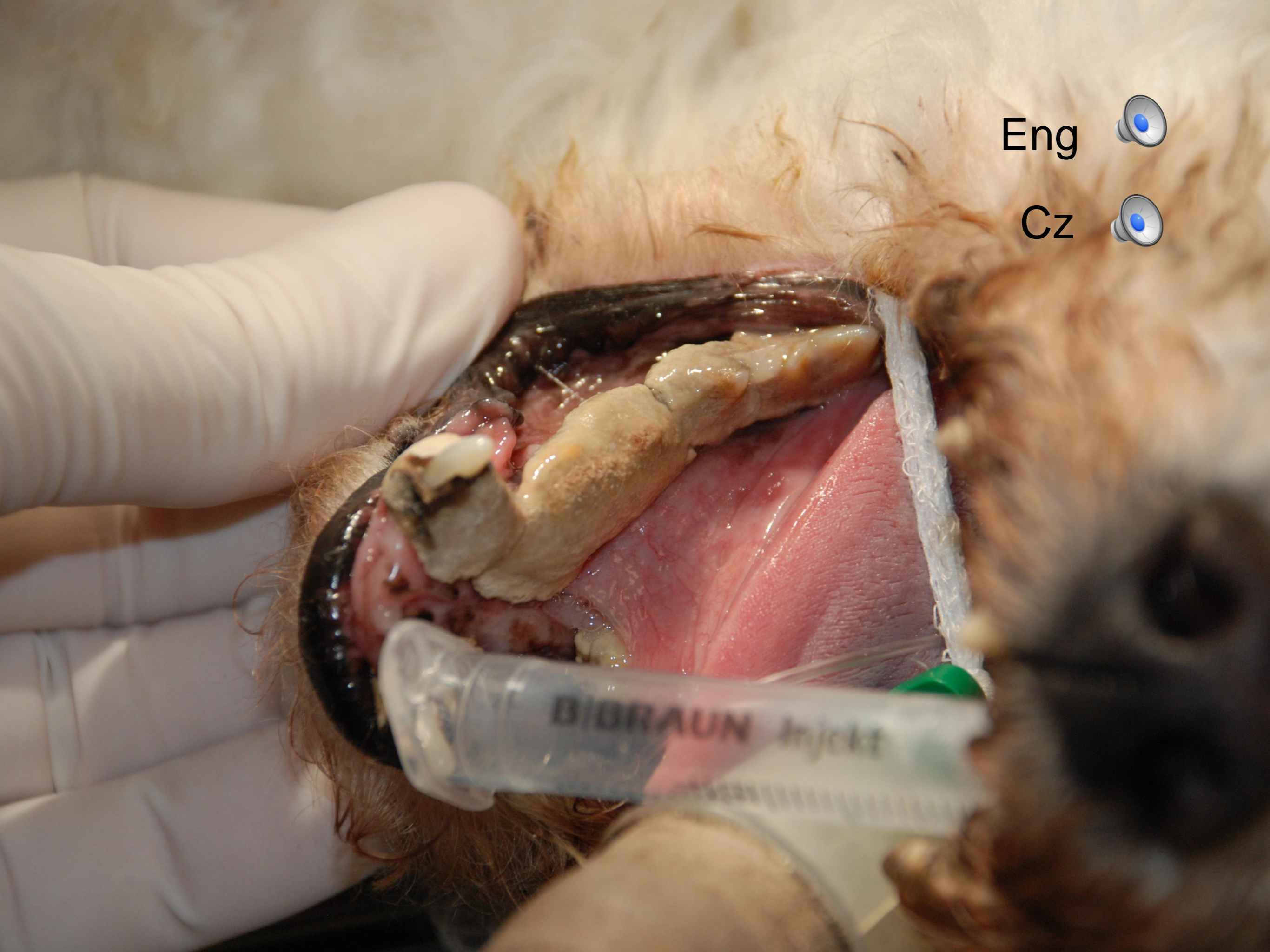

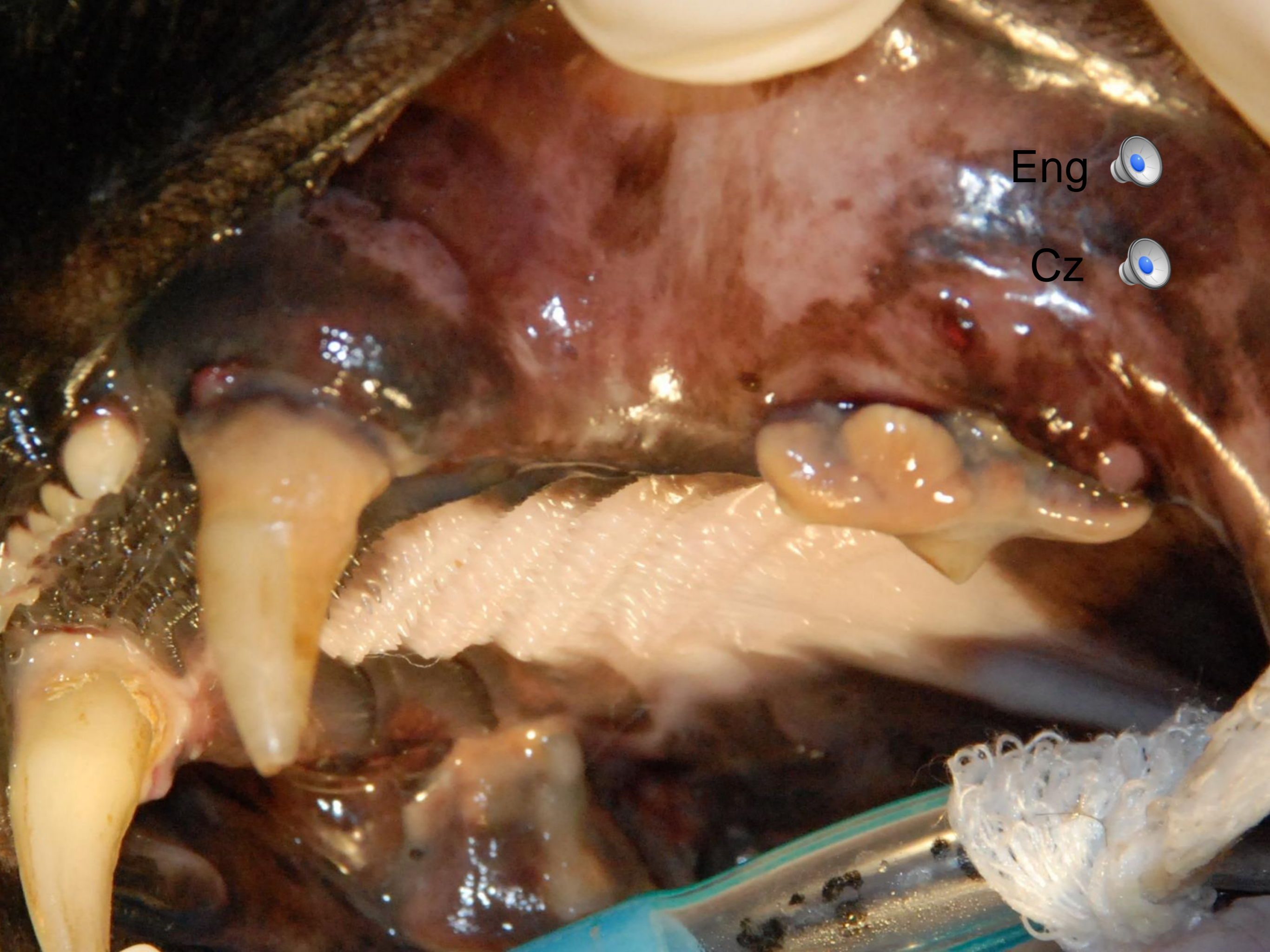


Eng



Cz





Eng 

Cz 





# Solutions

Eng 


Cz 

# Root fx.

## CROWN FX

- Ⓐ  • NO TX NEEDED.
- Ⓑ  • POLISH JAGGED EDGES.
- Ⓒ  • DENTIN EXPOSED. RESTORE.
- Ⓓ  • PULPA EXPOSED. ENDOODONTIC THERAPY.

## CROWN AND ROOT FX

- Ⓐ  • UNCOMPLICATED.
- Ⓑ  • COMPLICATED.
- Ⓒ  • LONG AXIS FR. EXTRACTION!!

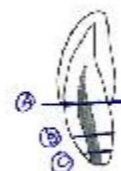Eng



Cz

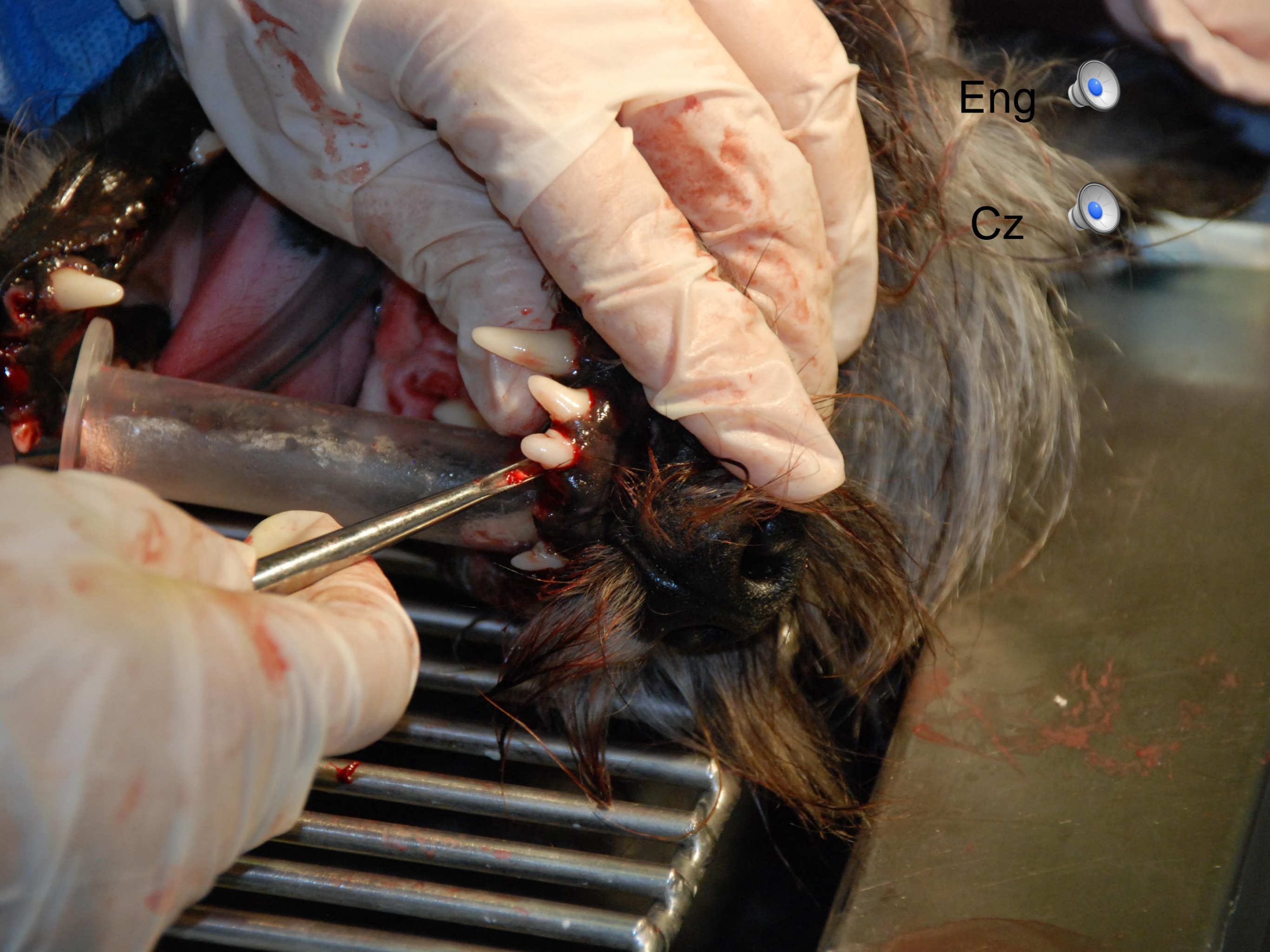

## Root fx.



- Ⓐ CORONAL ROOT-UNLIKELY TO HEAL. EXTRACT OR ENDODONTIC TREATMENT.
  - Ⓑ MIDROOT FX
  - Ⓒ APICAL SEGMENT FX
- } WILL HEAL WITH IMMOBILIZATION.

- Horizontal fx have better prognosis than oblique ones.
- Fr line in buccalis - EXTRACT!
- For fixation you can use: Acrylic material + soft surgical wire.

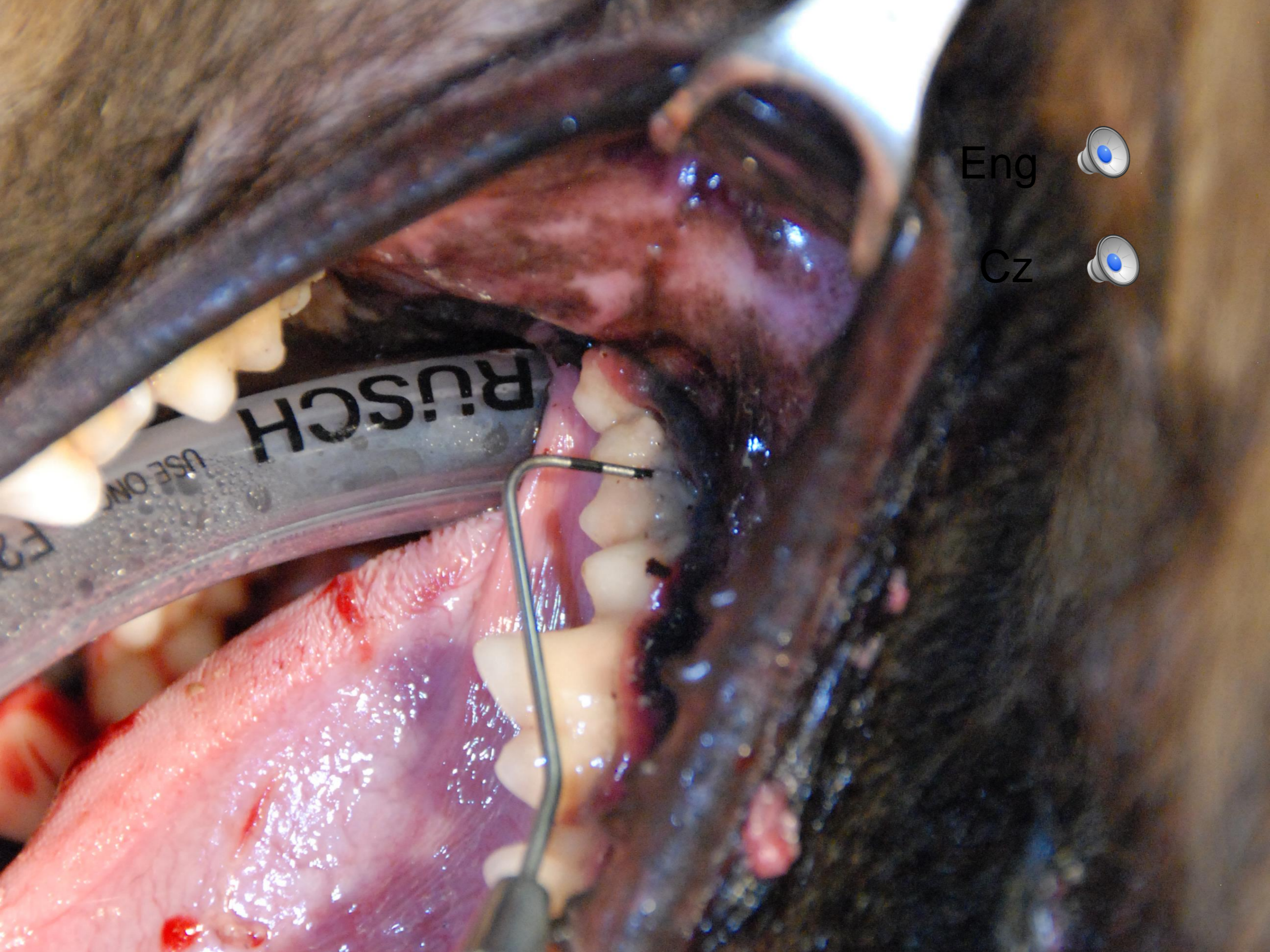


Eng



Cz



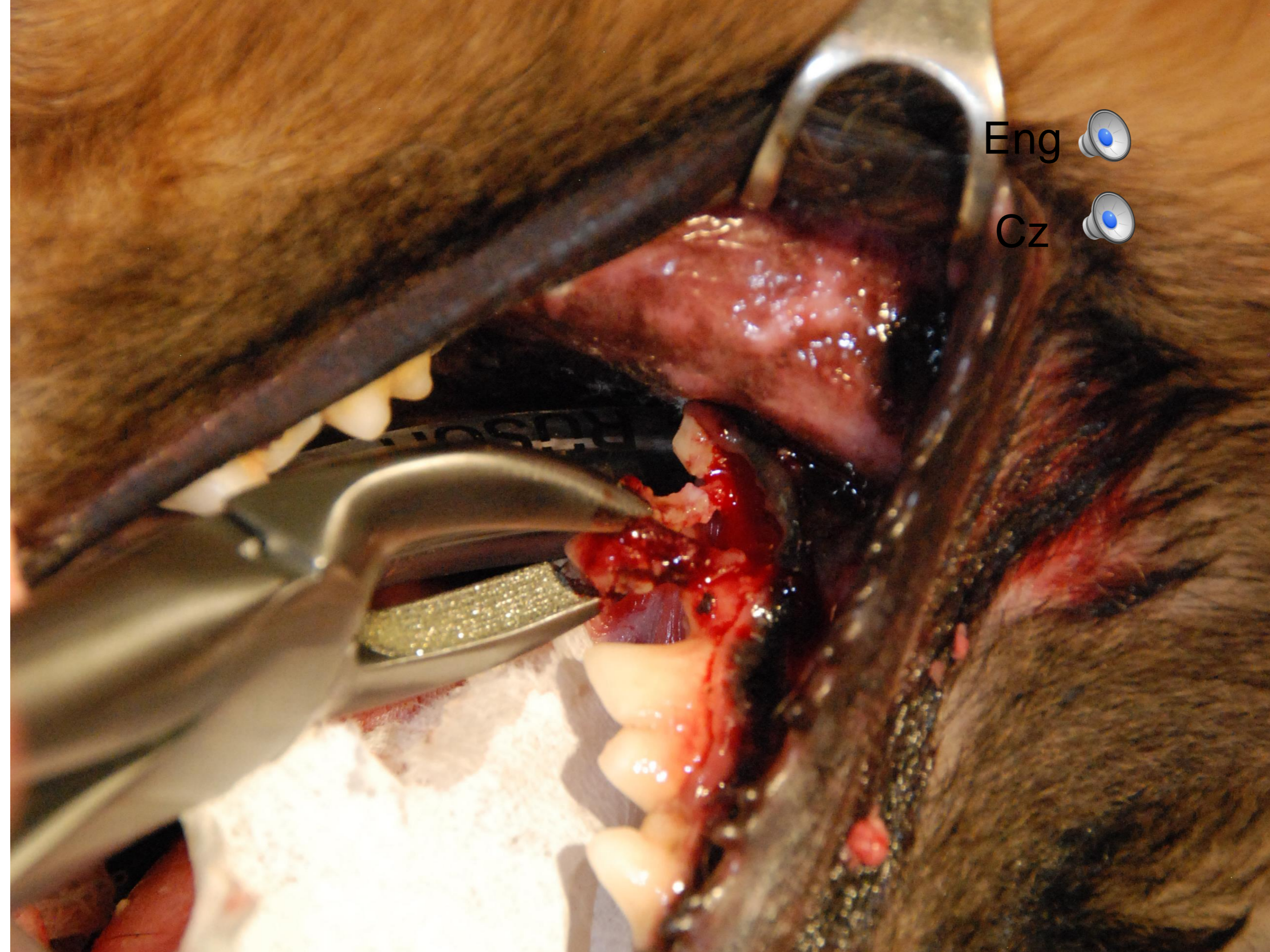

Eng



Cz



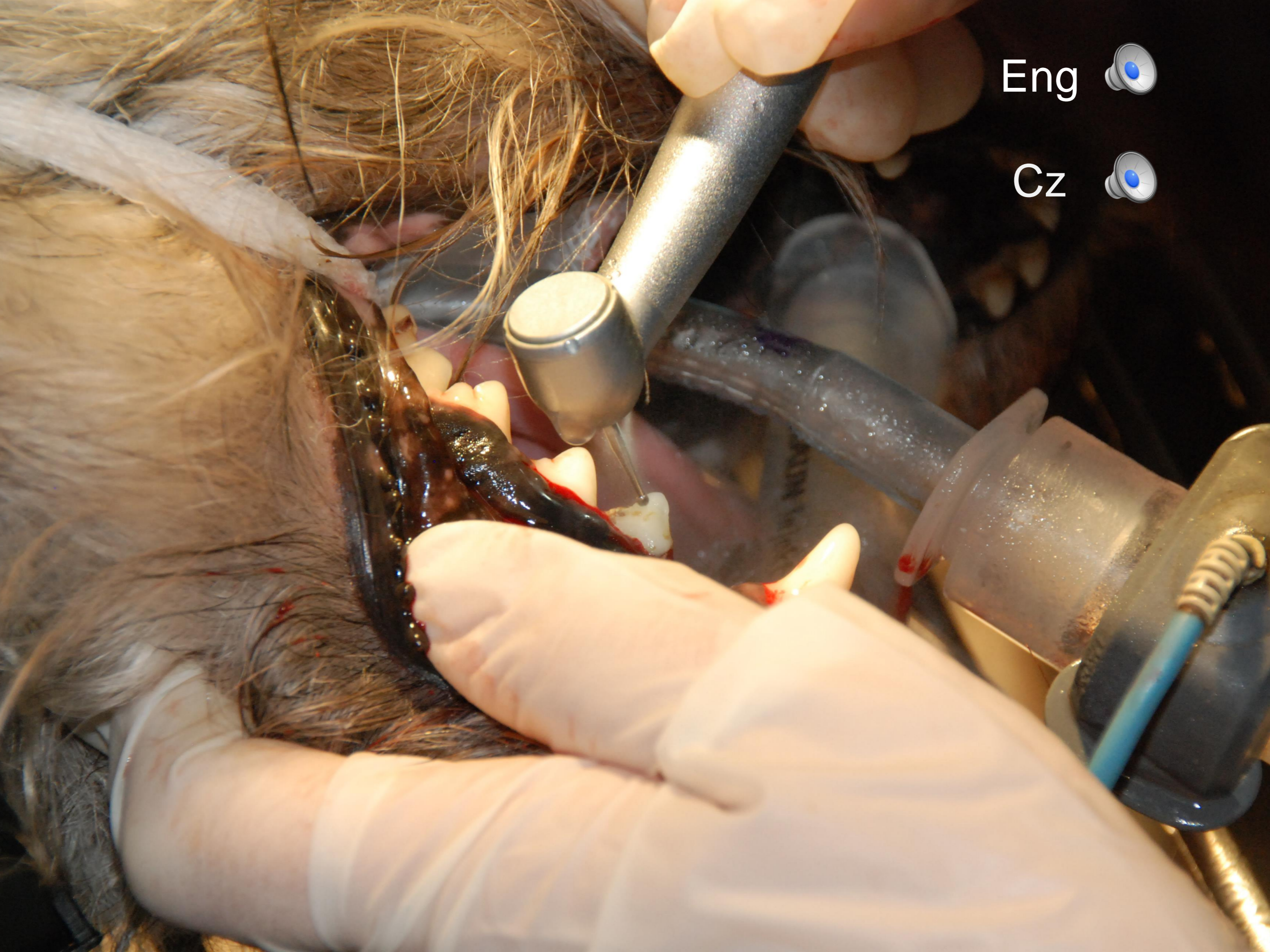

Eng



Cz

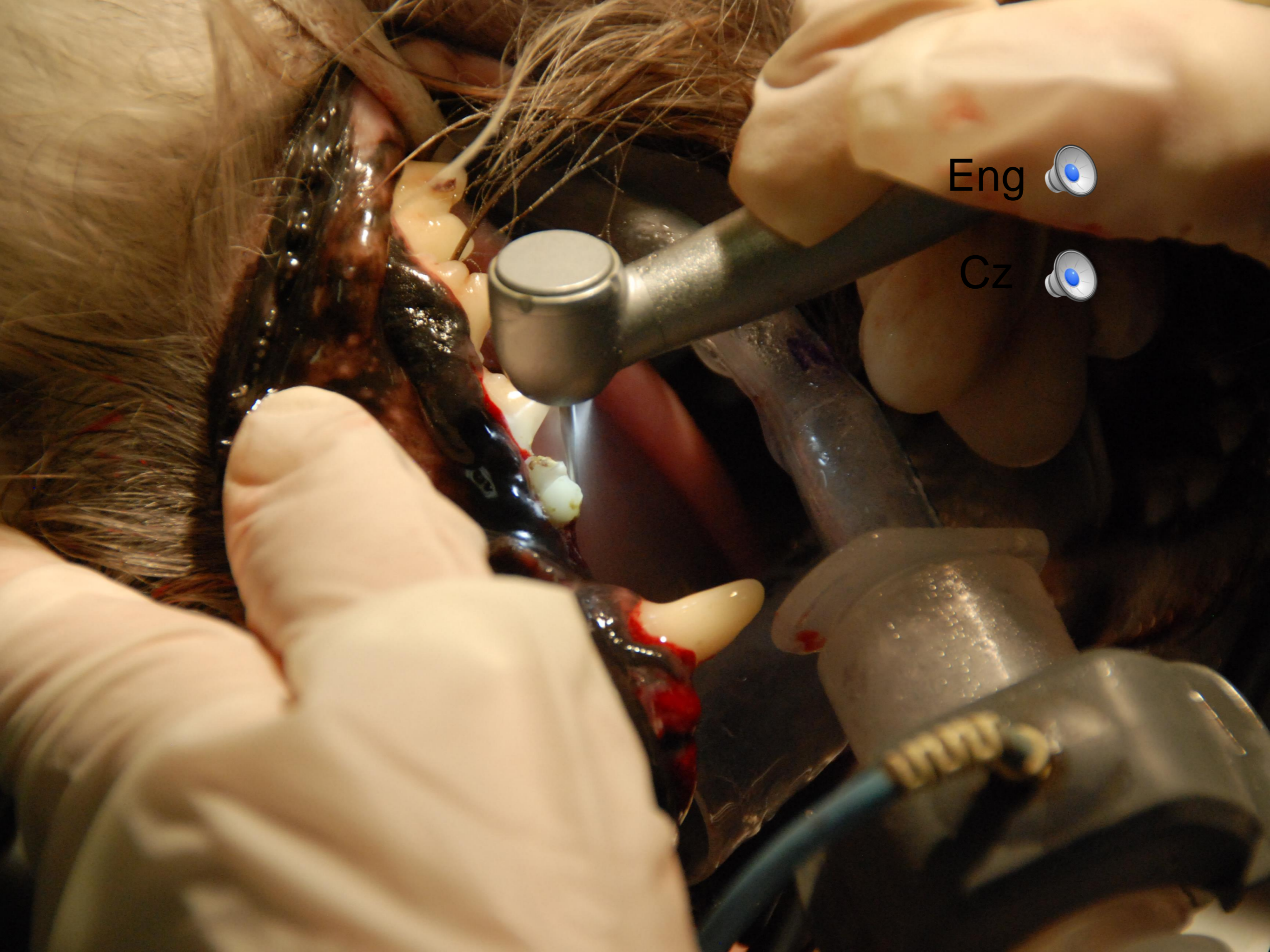




Eng 

Cz 



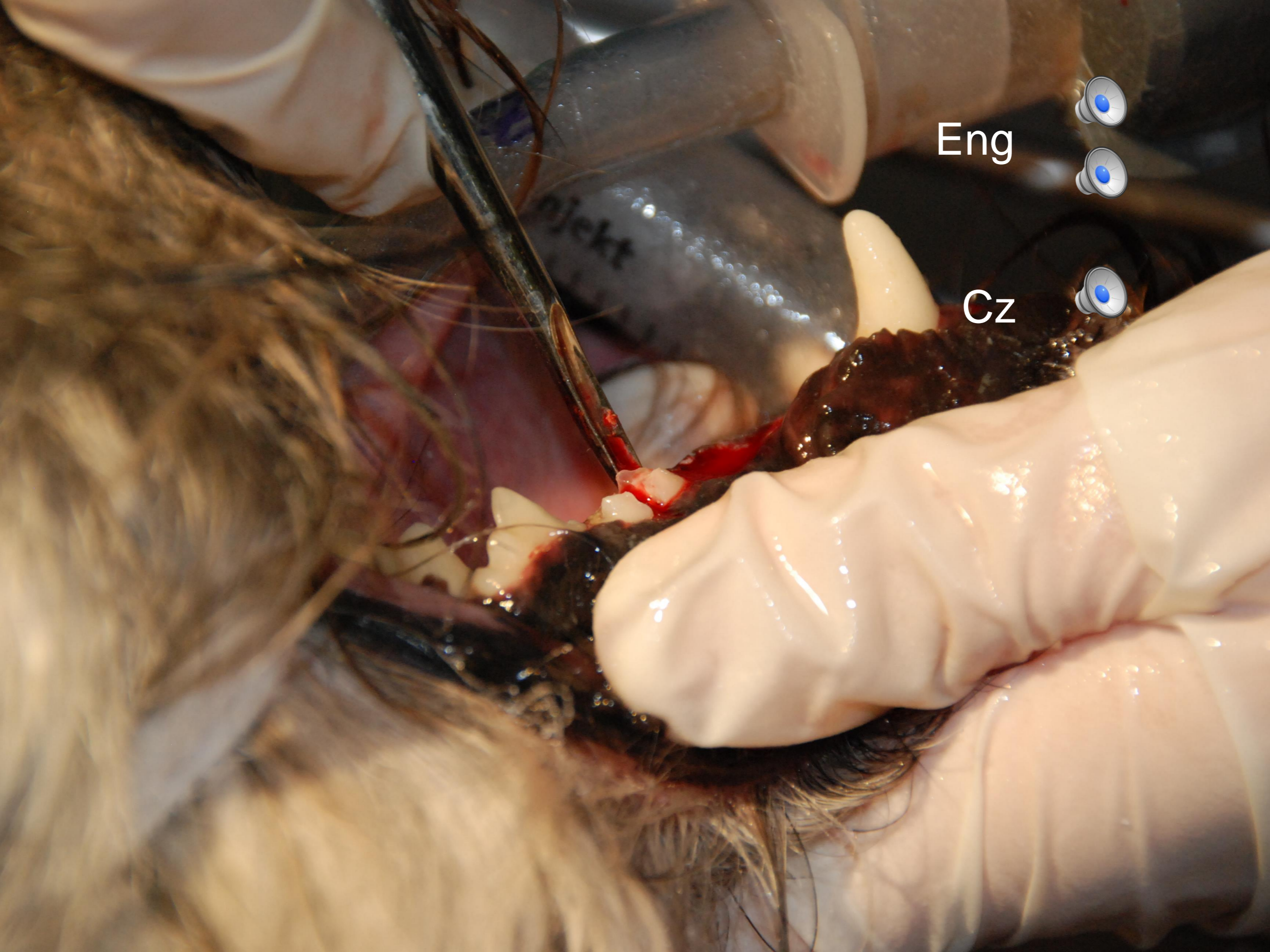


Eng



Cz









Eng

Cz



## CROWN FX

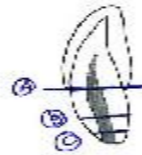
- Ⓐ  • NO TX NEEDED.
- Ⓑ  • POLISH JAGGED EDGES.
- Ⓒ  • DENTIN EXPOSED. RESTORE.
- Ⓓ  • PULPA EXPOSED. ENDODONTIC THERAPY.

# Eng



# Cz




## Root FX



- Ⓐ CORONAL ROOT-ULCERS TO HEAL EXTRACT OR ENDODONTIC TREATMENT.
- Ⓑ MIDROOT FX
- Ⓒ APICAL SEGMENT FX } WILL HEAL WITH IMMOBILIZATION.

- Horizontal fx have better prognosis than oblique ones.
- FX line in buccal axis - EXTRACT!
- For fixation you can use: Acrylic material + soft surgical wire.

## CROWN AND ROOT FX

- Ⓐ  • UNCOMPLICATED.
- Ⓑ  • COMPLICATED.
- Ⓒ  • LONG AXIS FX. EXTRACTION!!

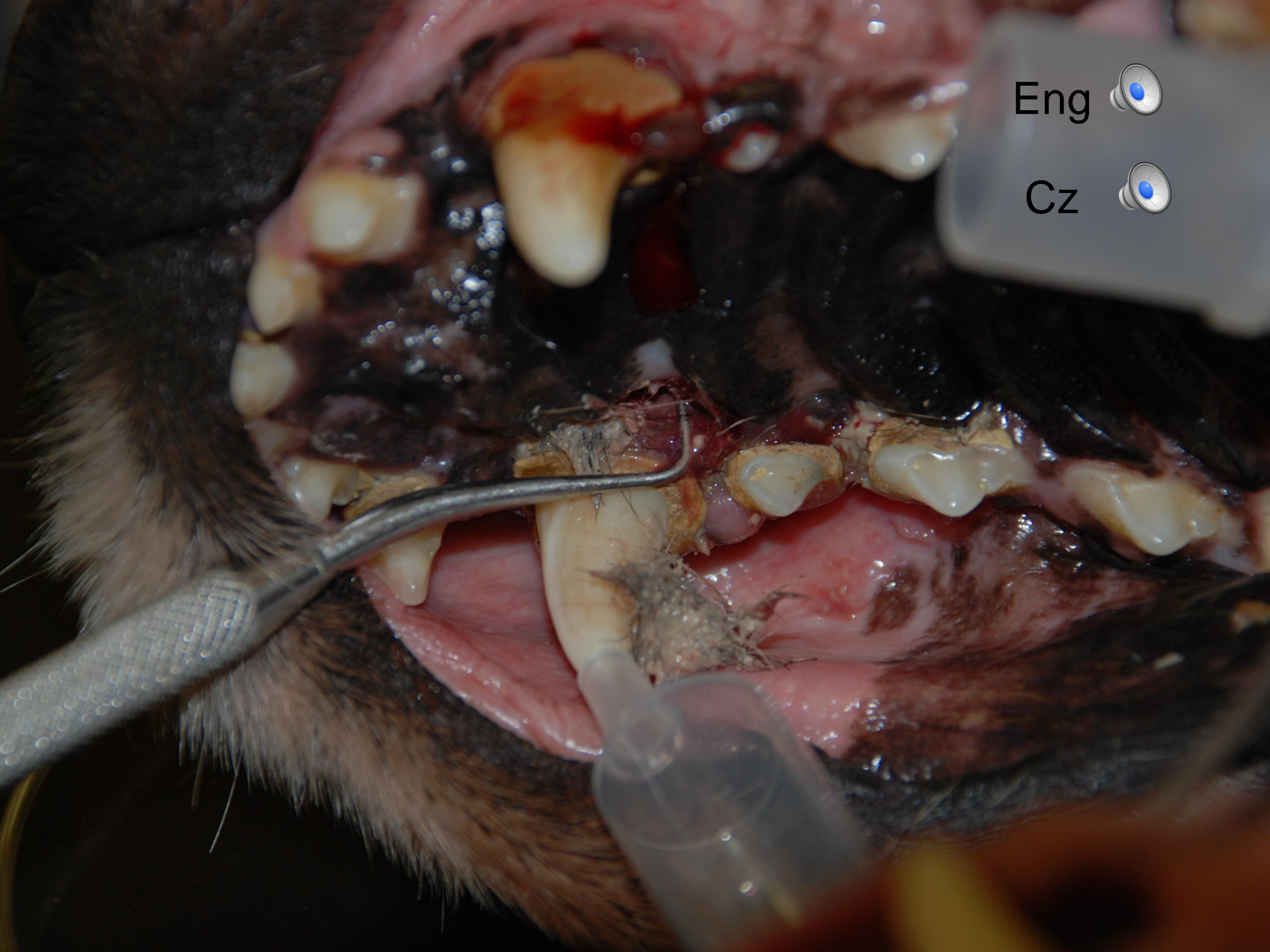# *ONF*

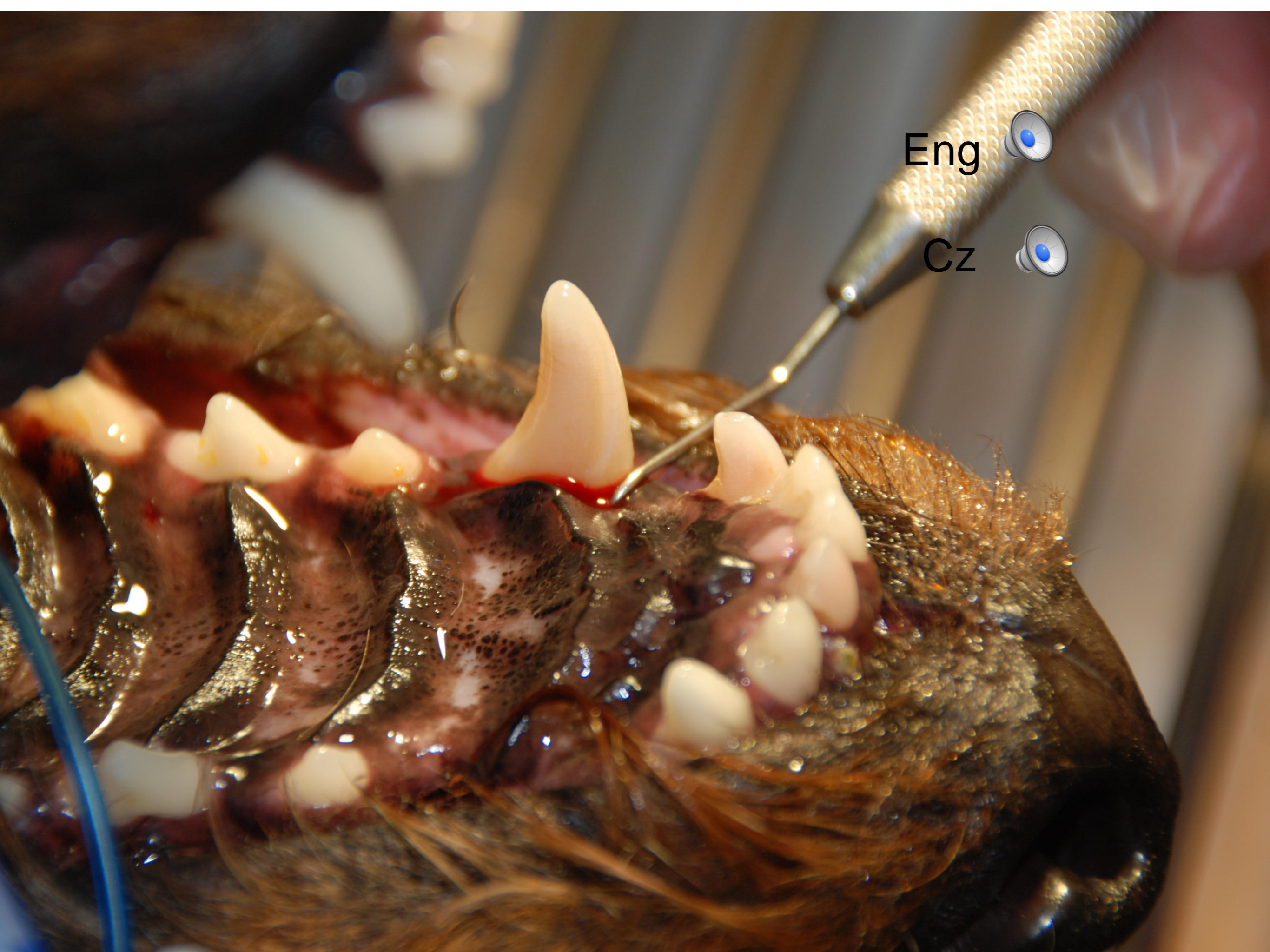
Eng 

Cz 

Eng 

Cz 



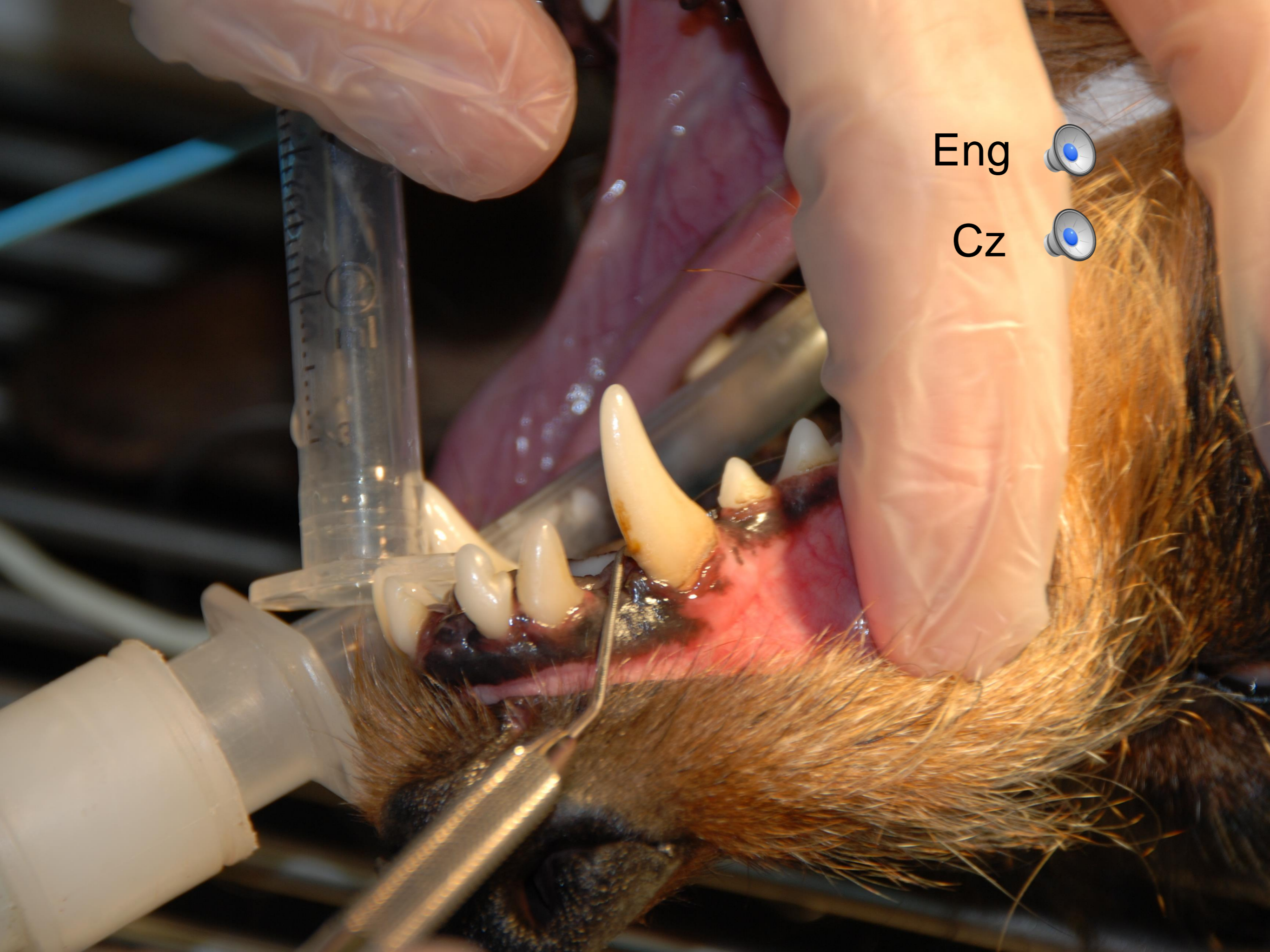


Eng



Cz



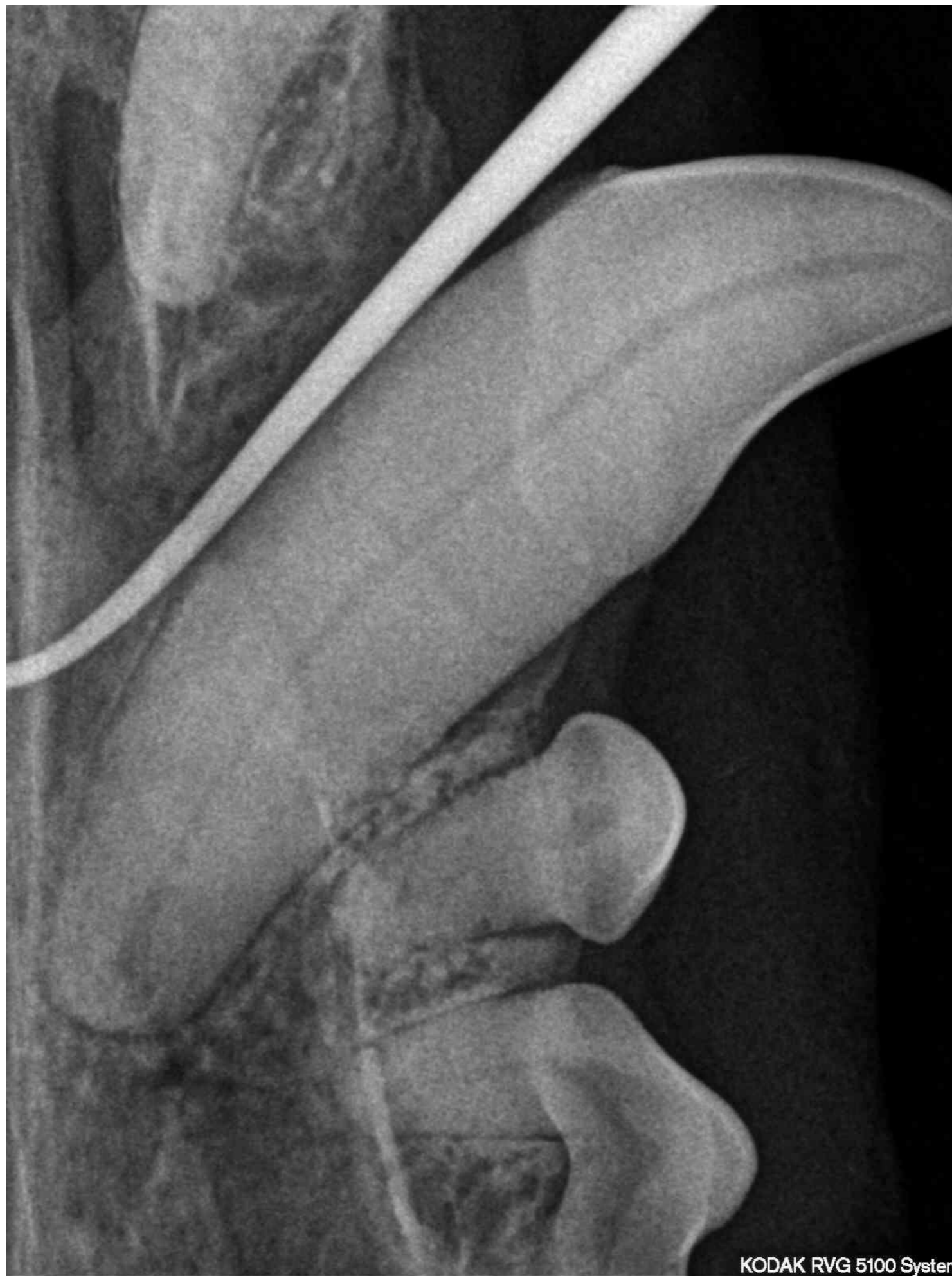


Eng



Cz

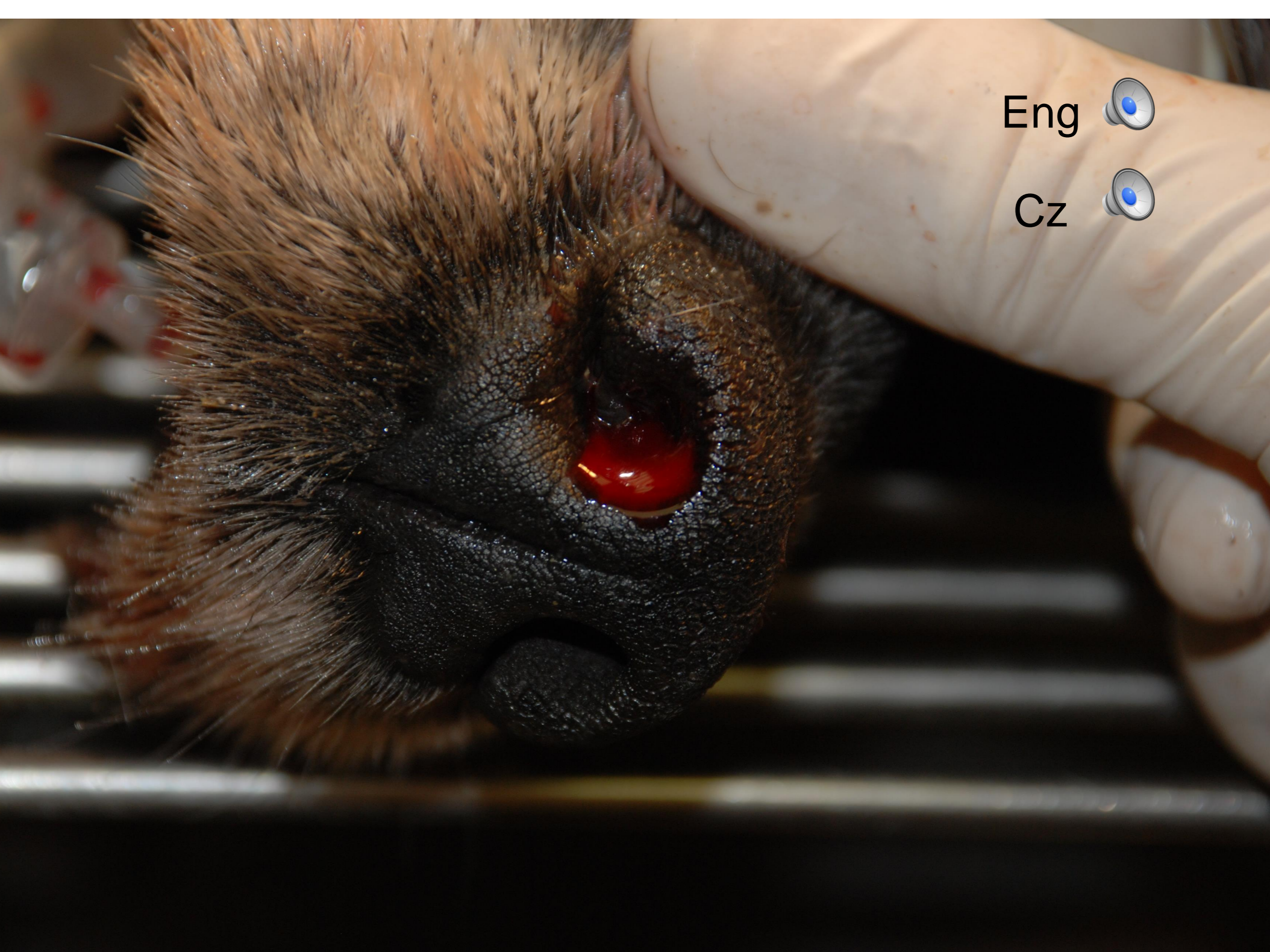



Eng 

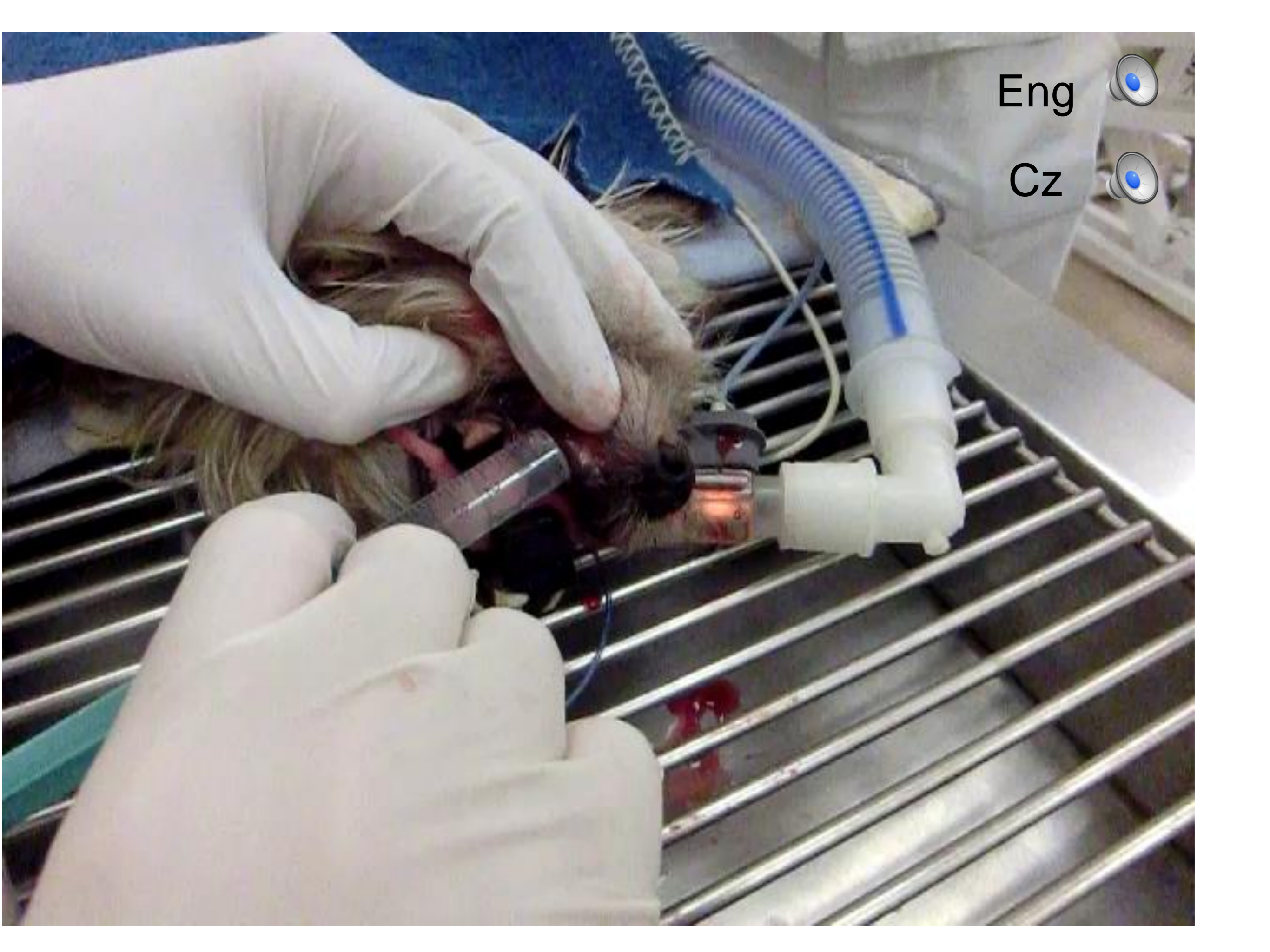Cz 





Eng 

Cz 



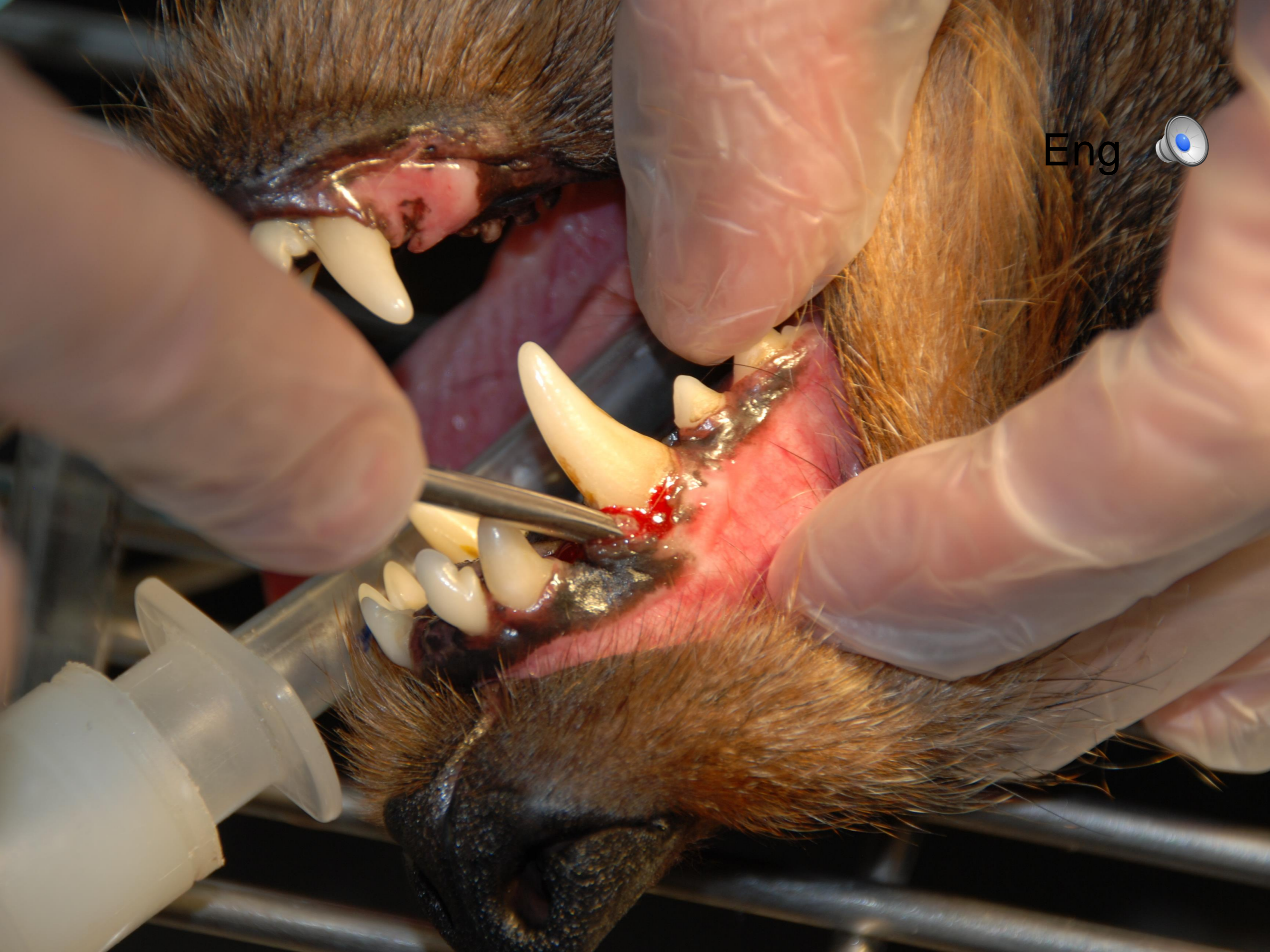Eng

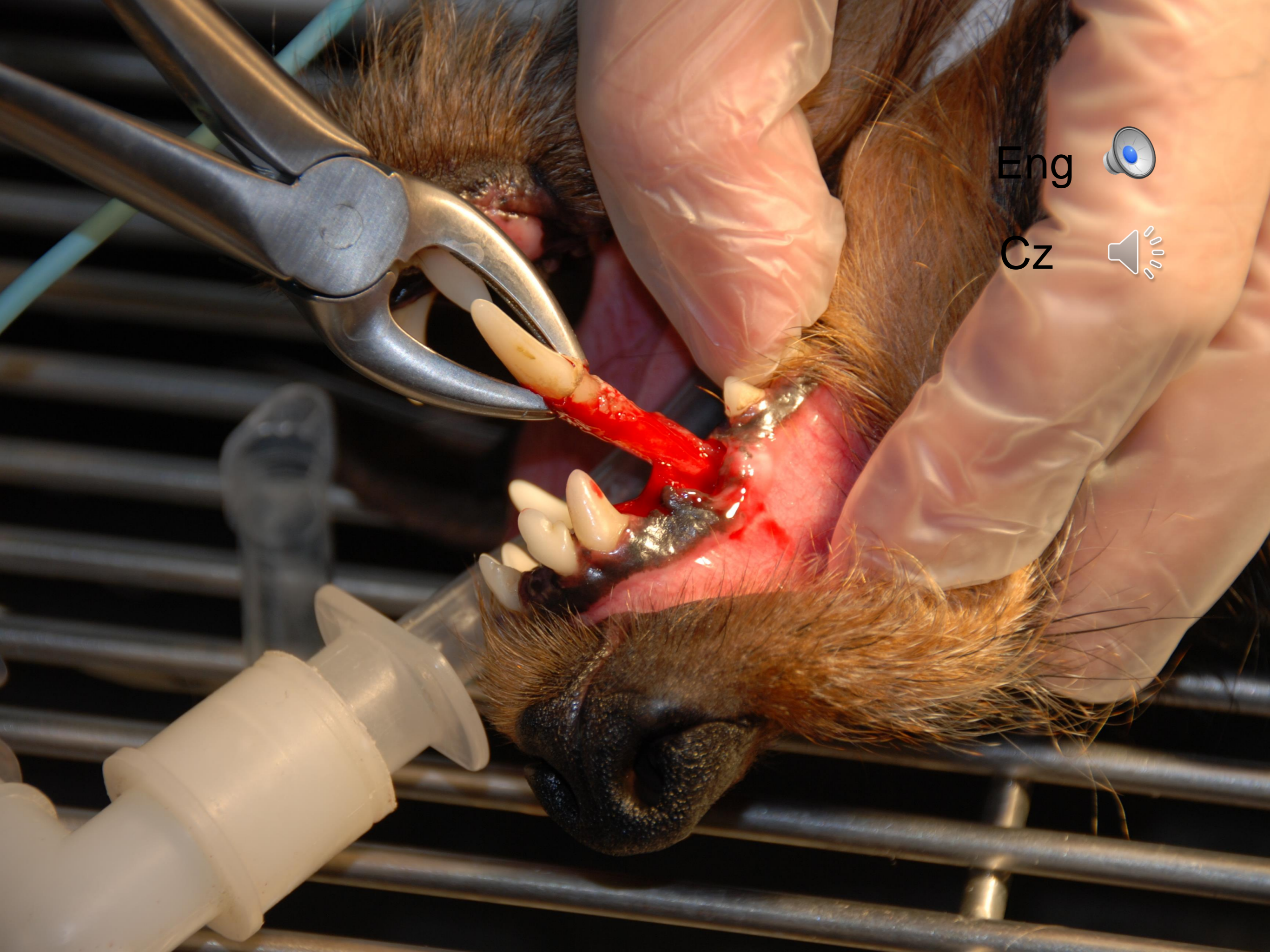

Cz



Eng



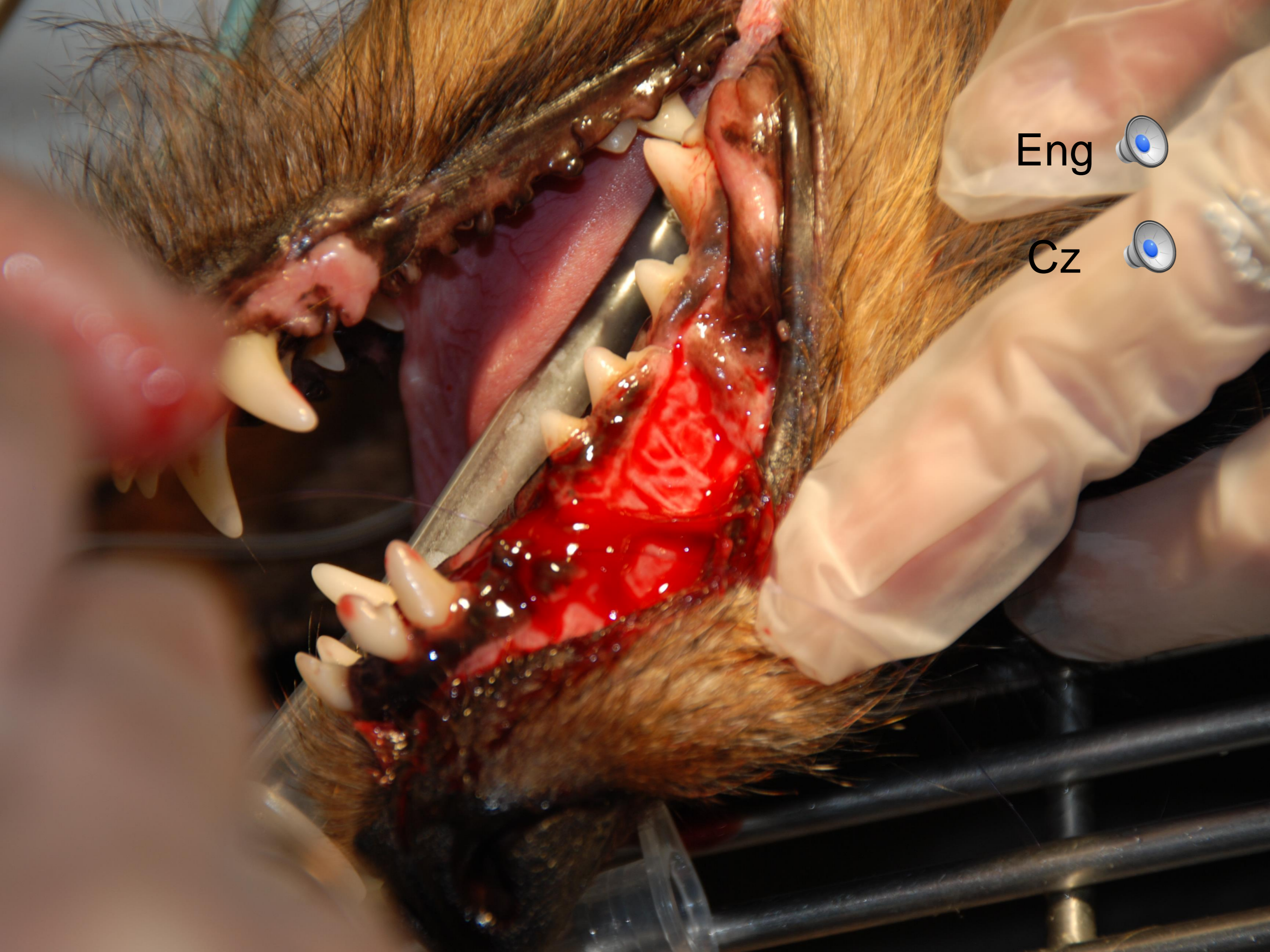


Eng



Cz



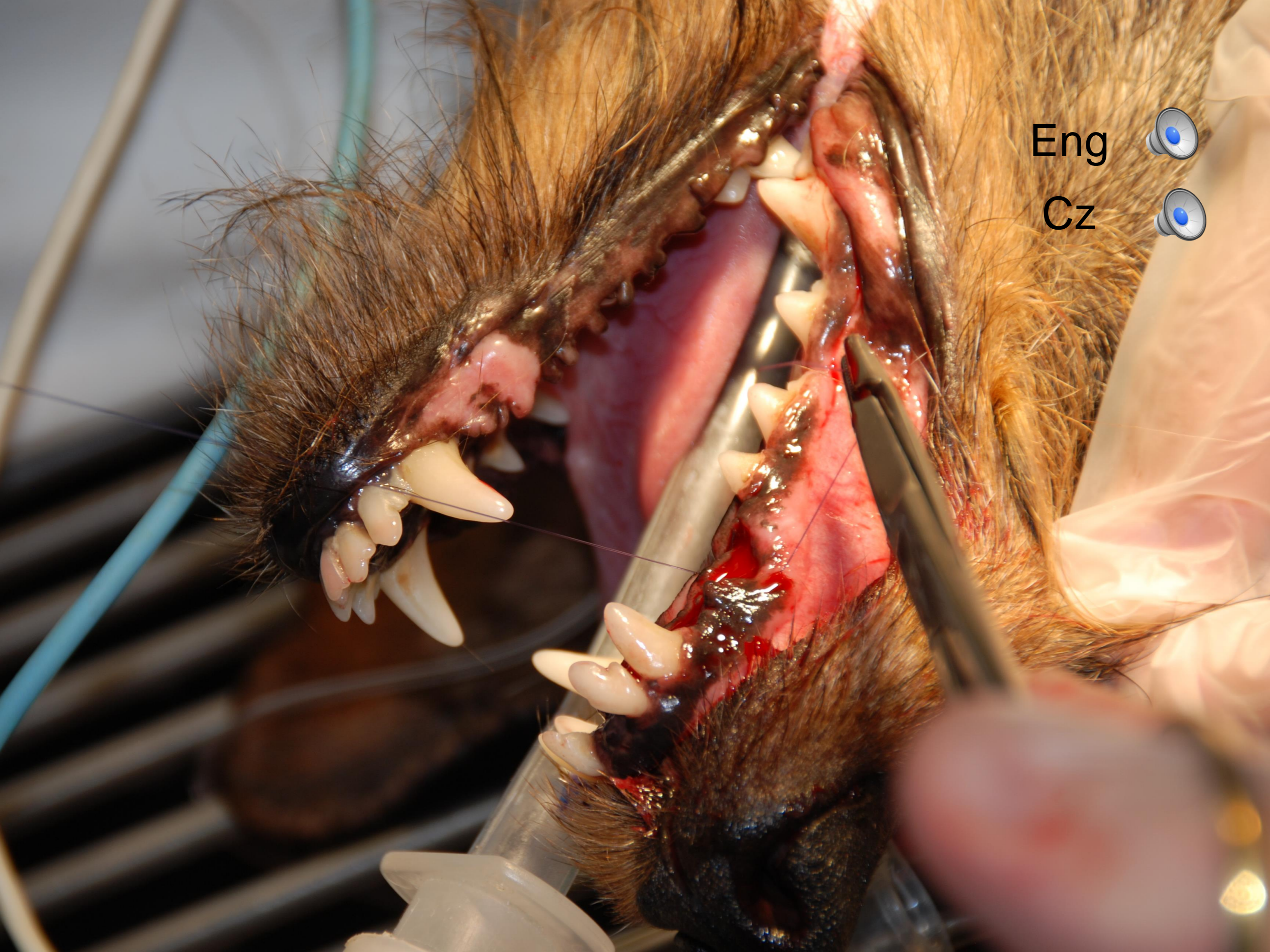

Eng



Cz





Eng



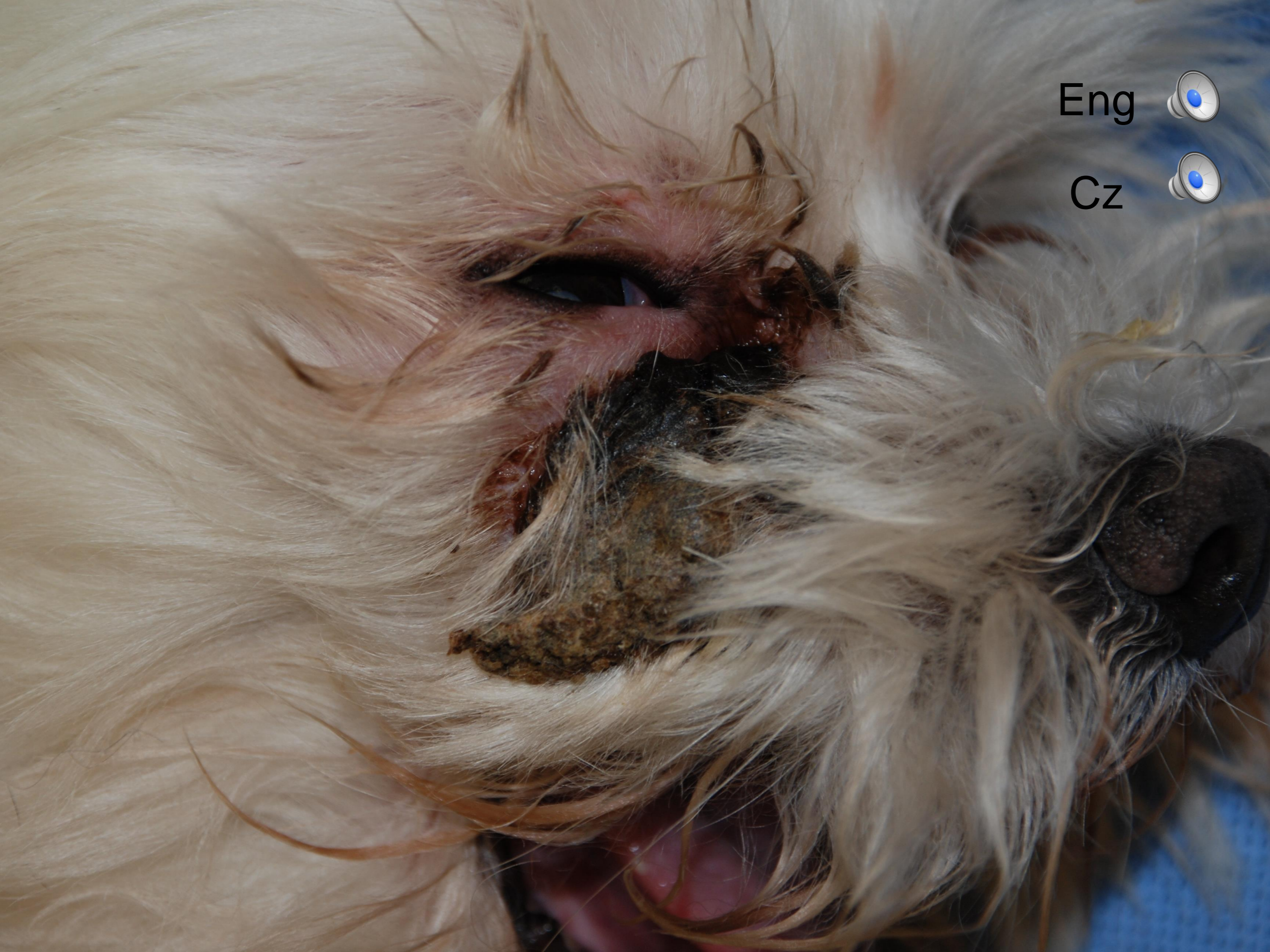Cz



# OFF

Eng 

Cz 



Eng



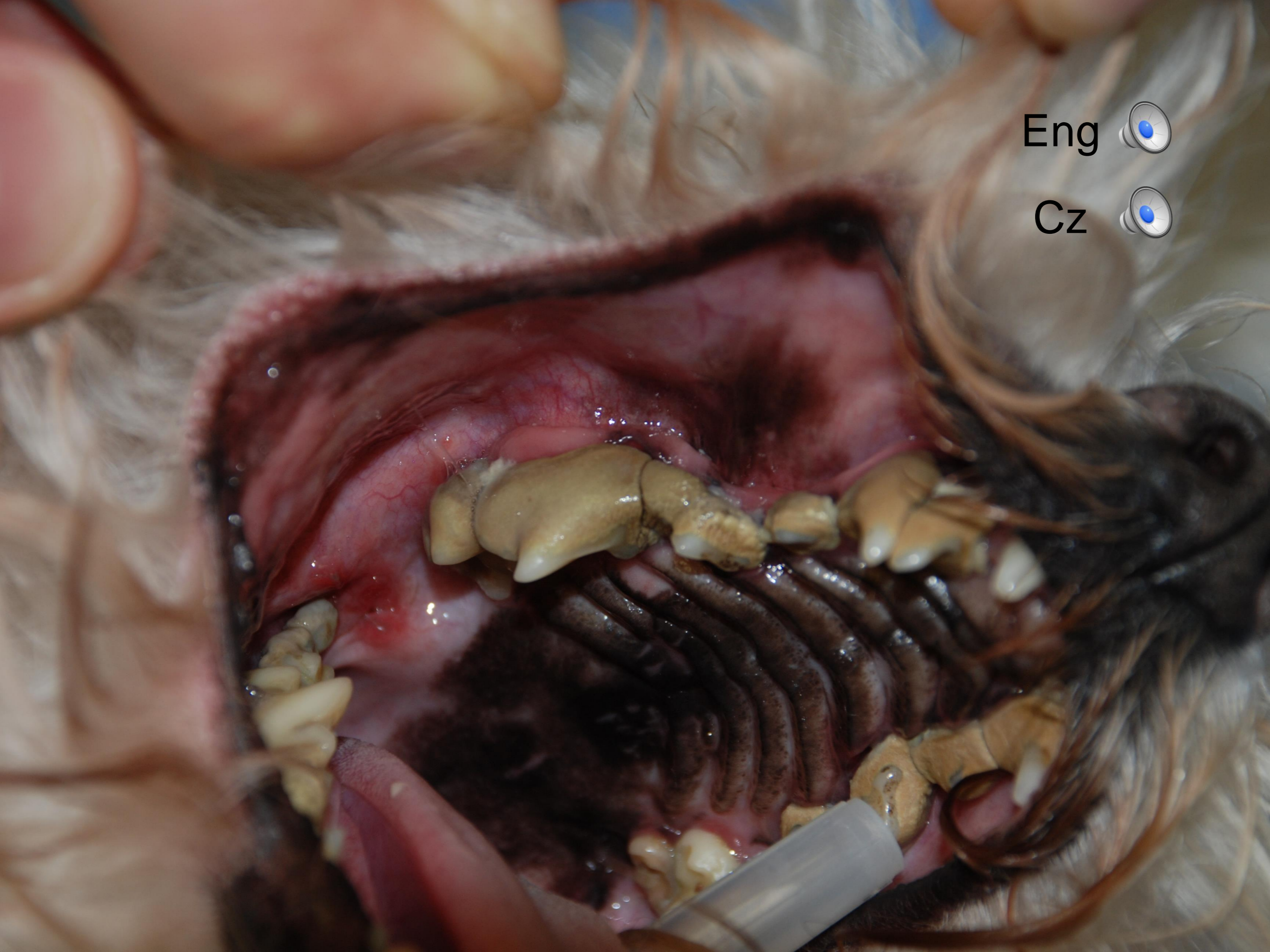Cz





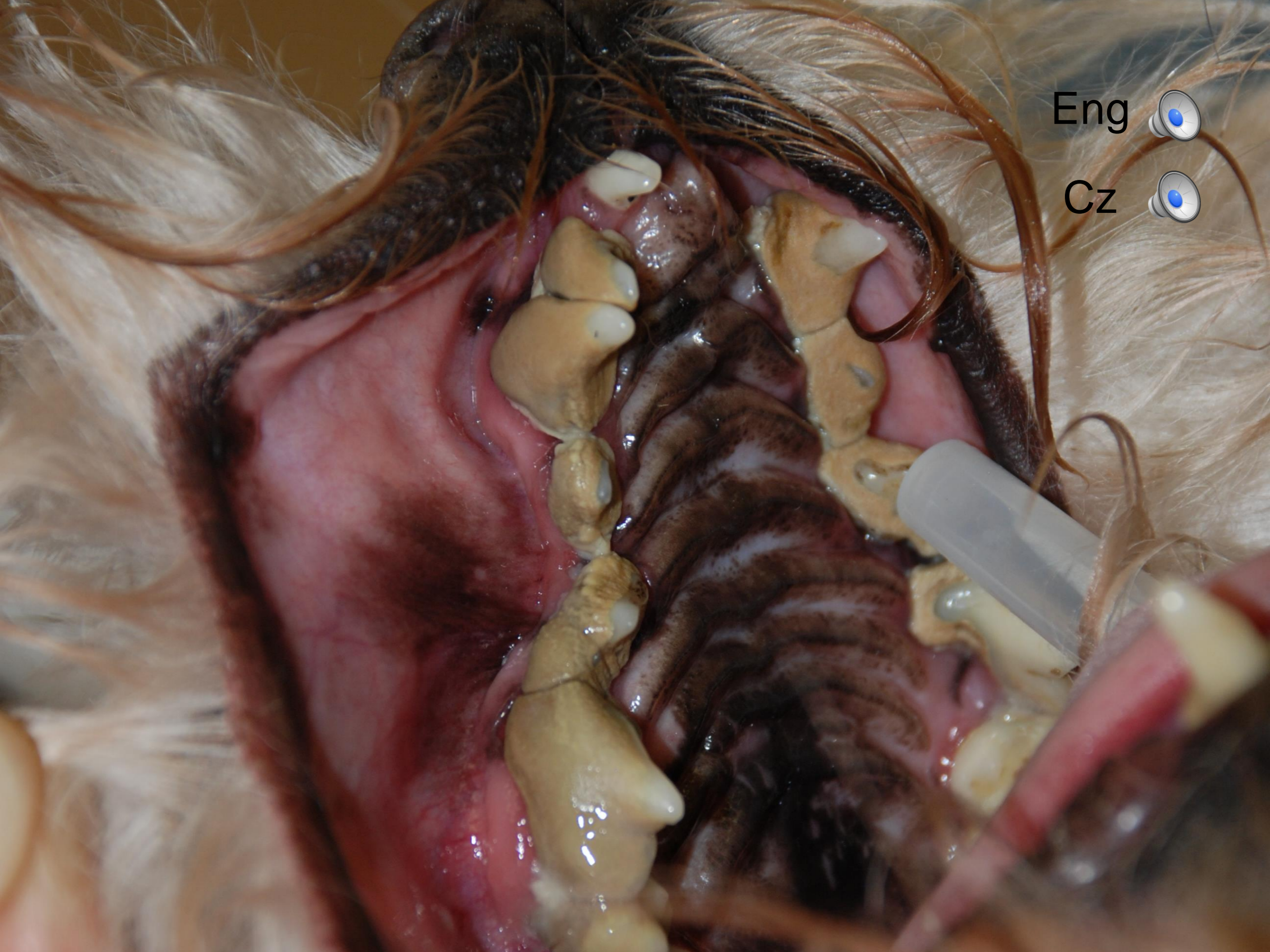Eng 

Cz 



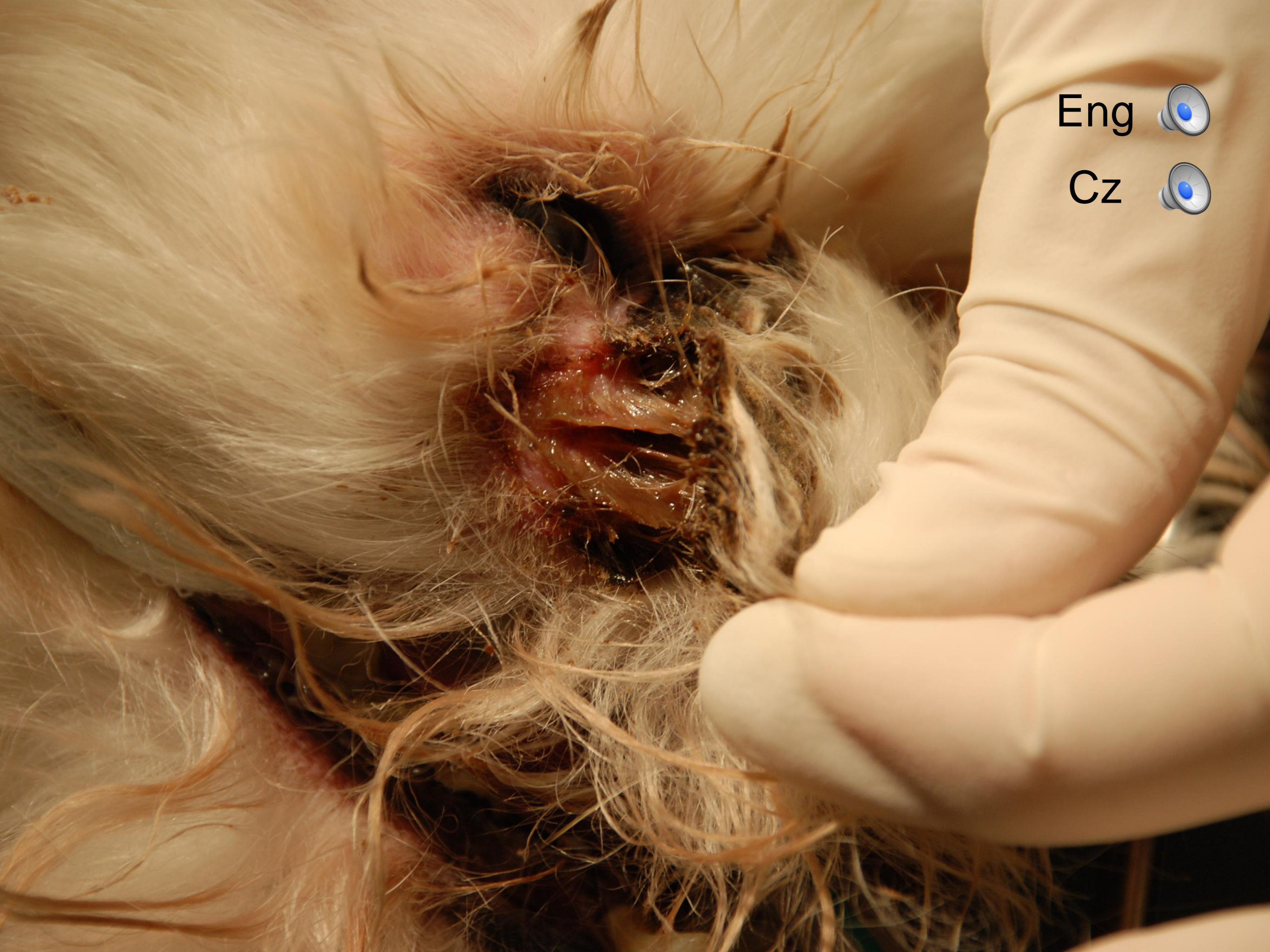Eng 

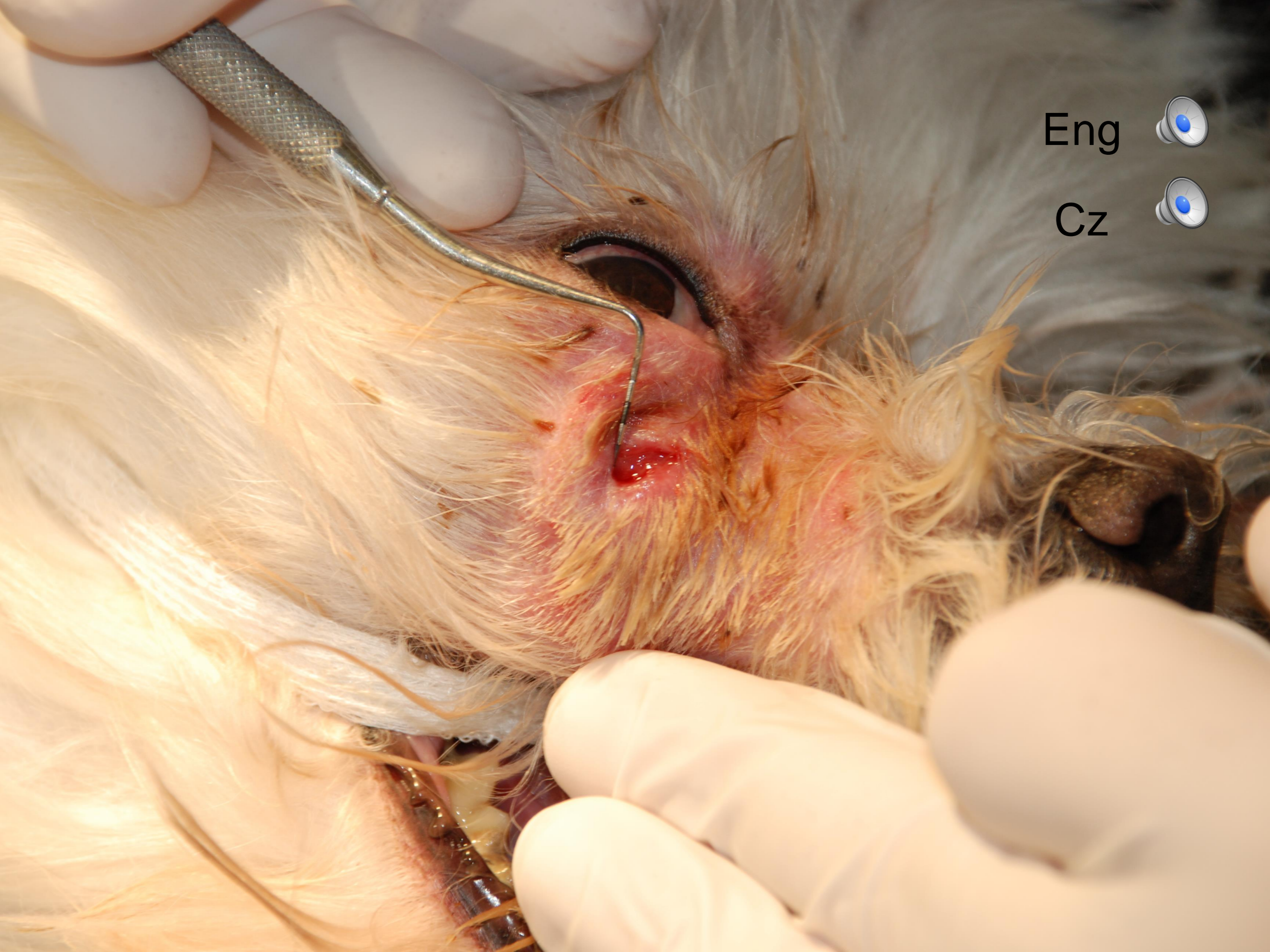Cz 



Eng 

Cz 



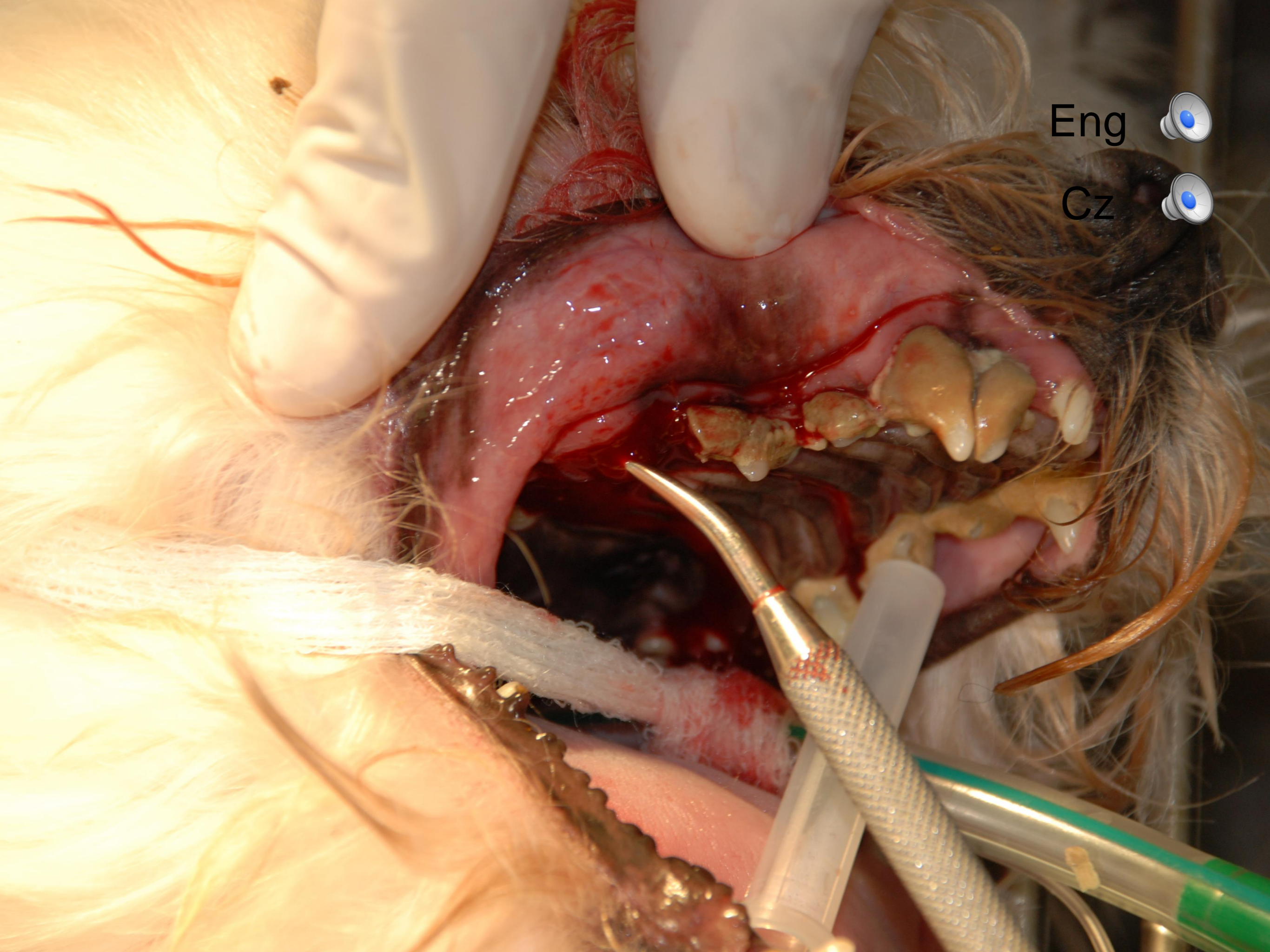


Eng



Cz



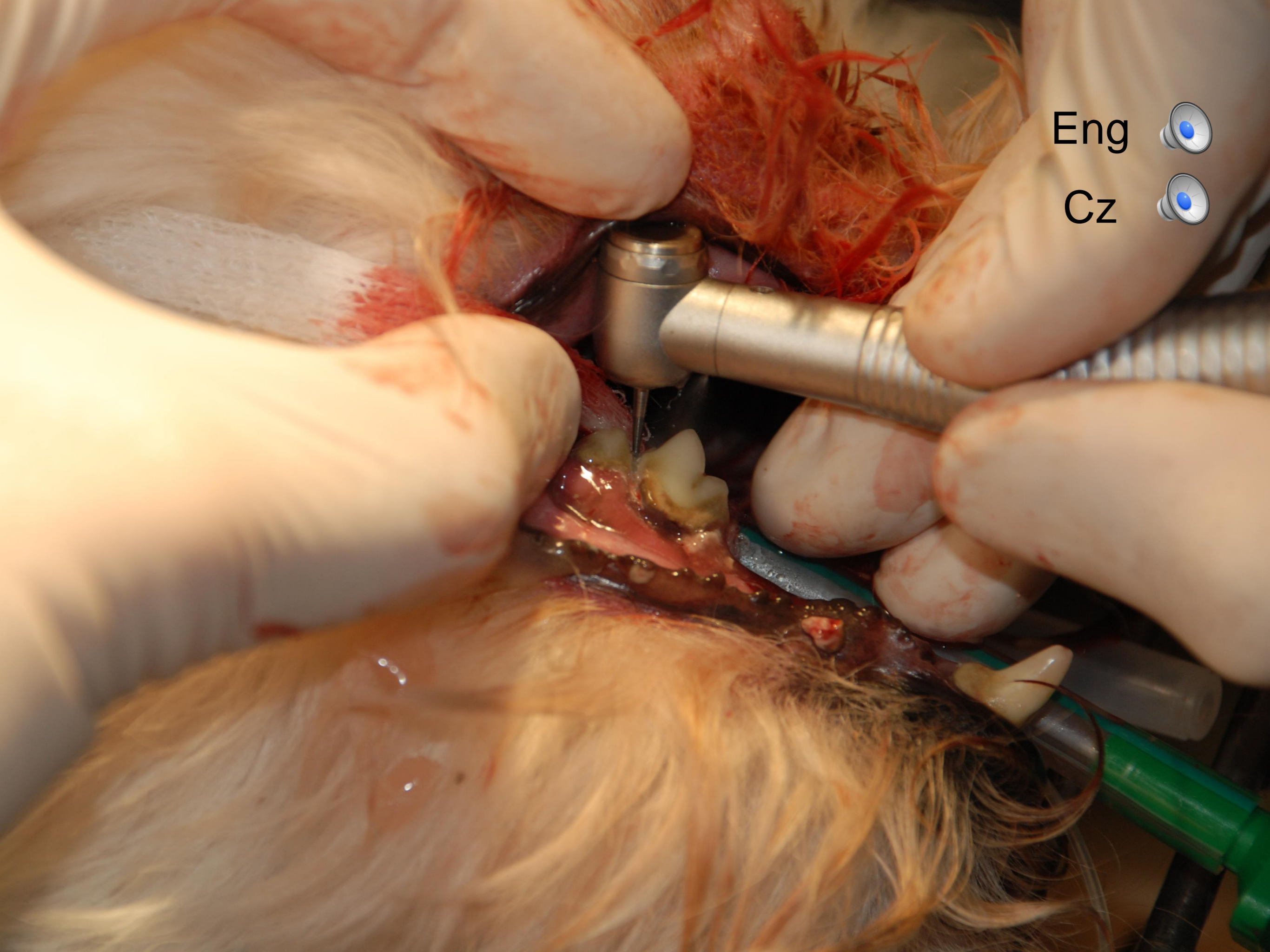

Eng



Cz



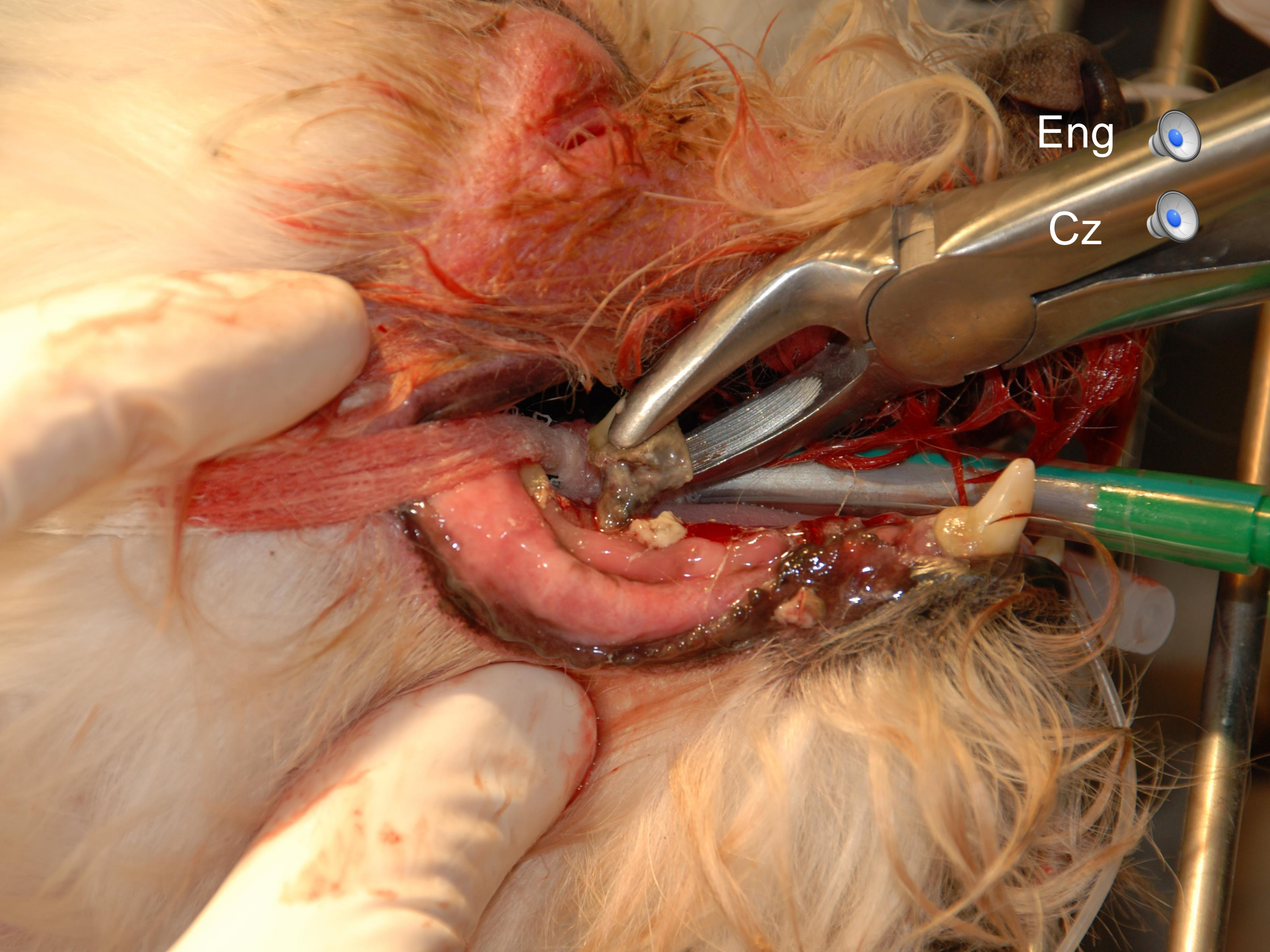


Eng



Cz





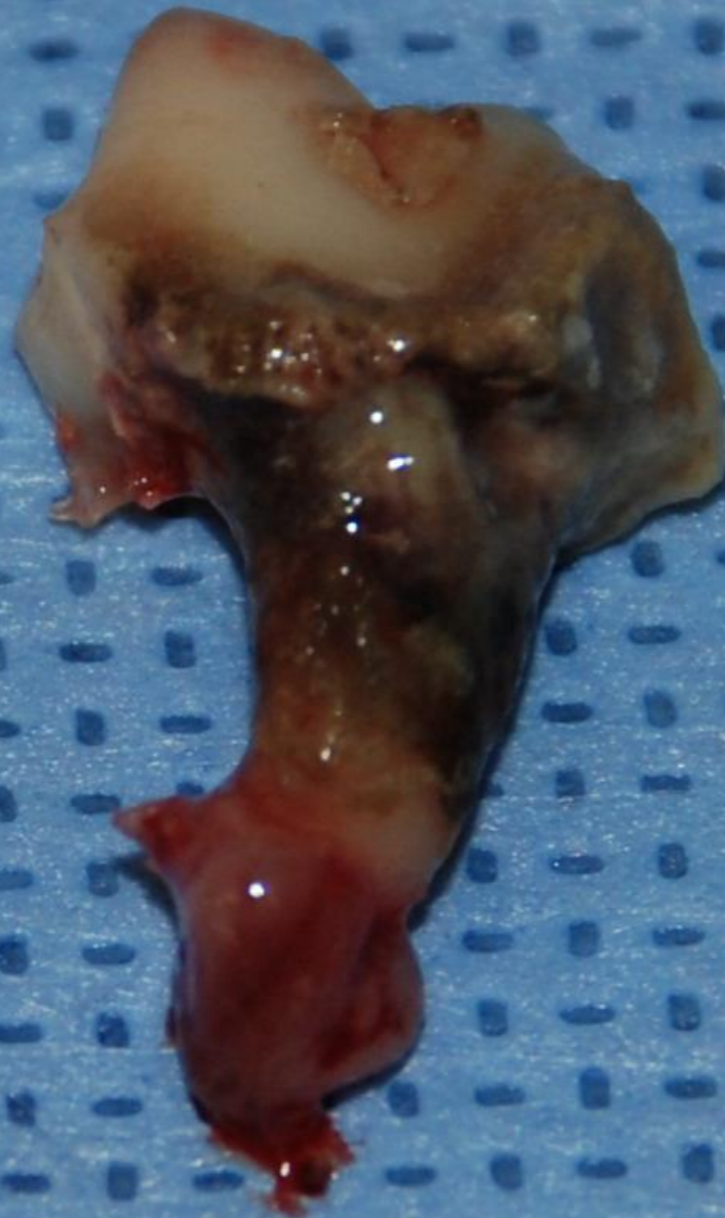Eng 

Cz 

Eng



Cz

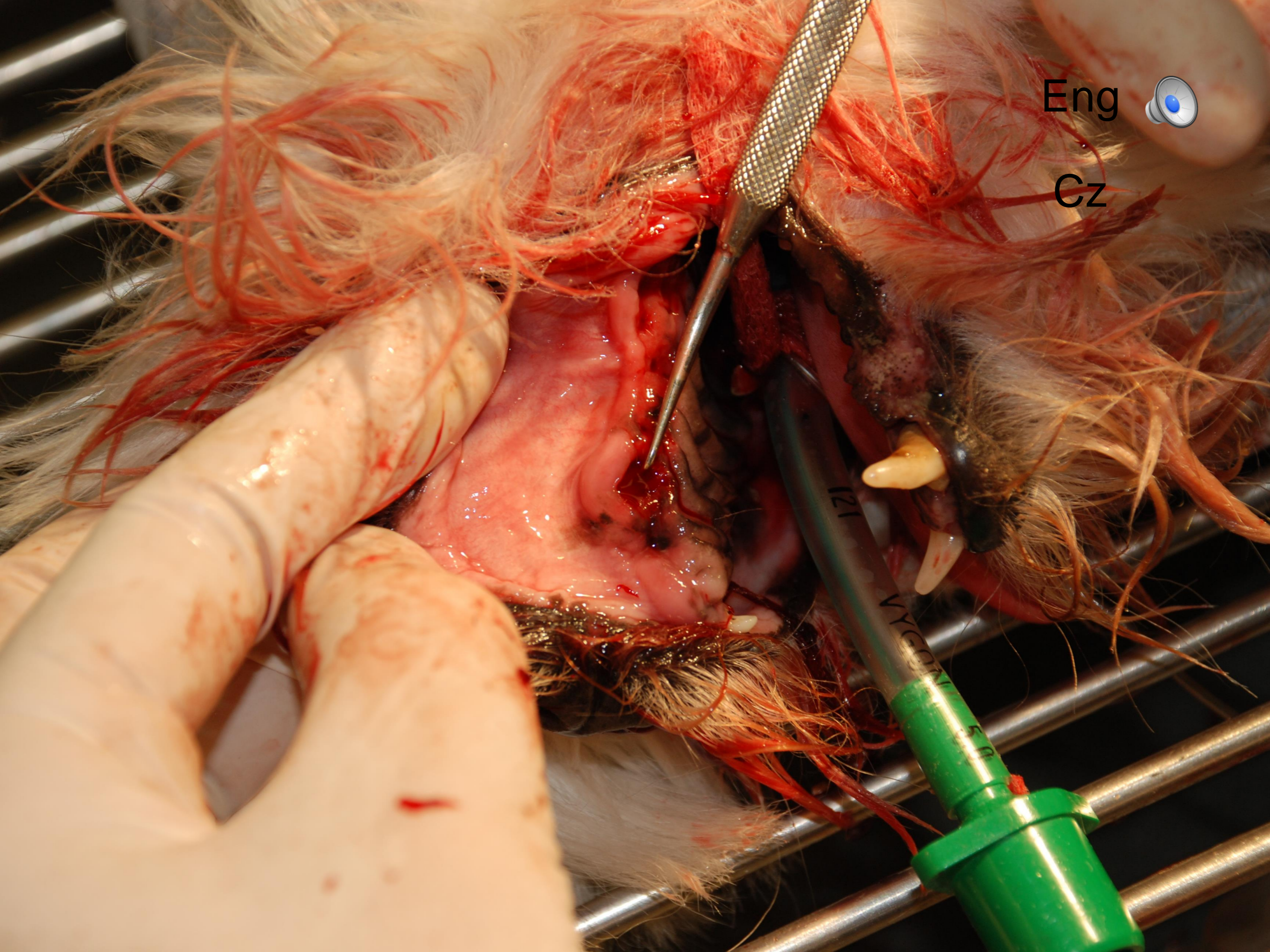




Eng



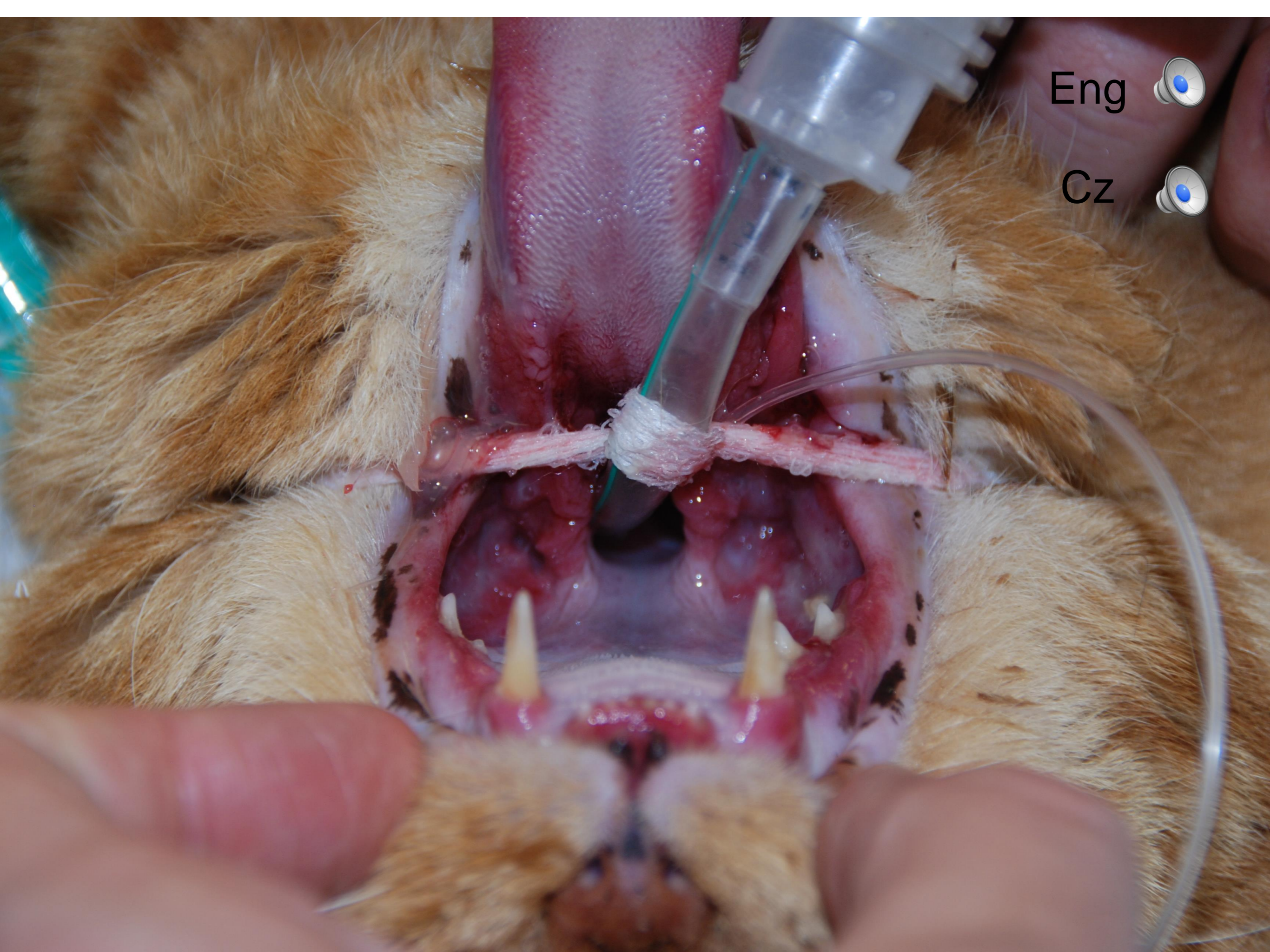Cz



# Stomatitis

Eng 

Cz 

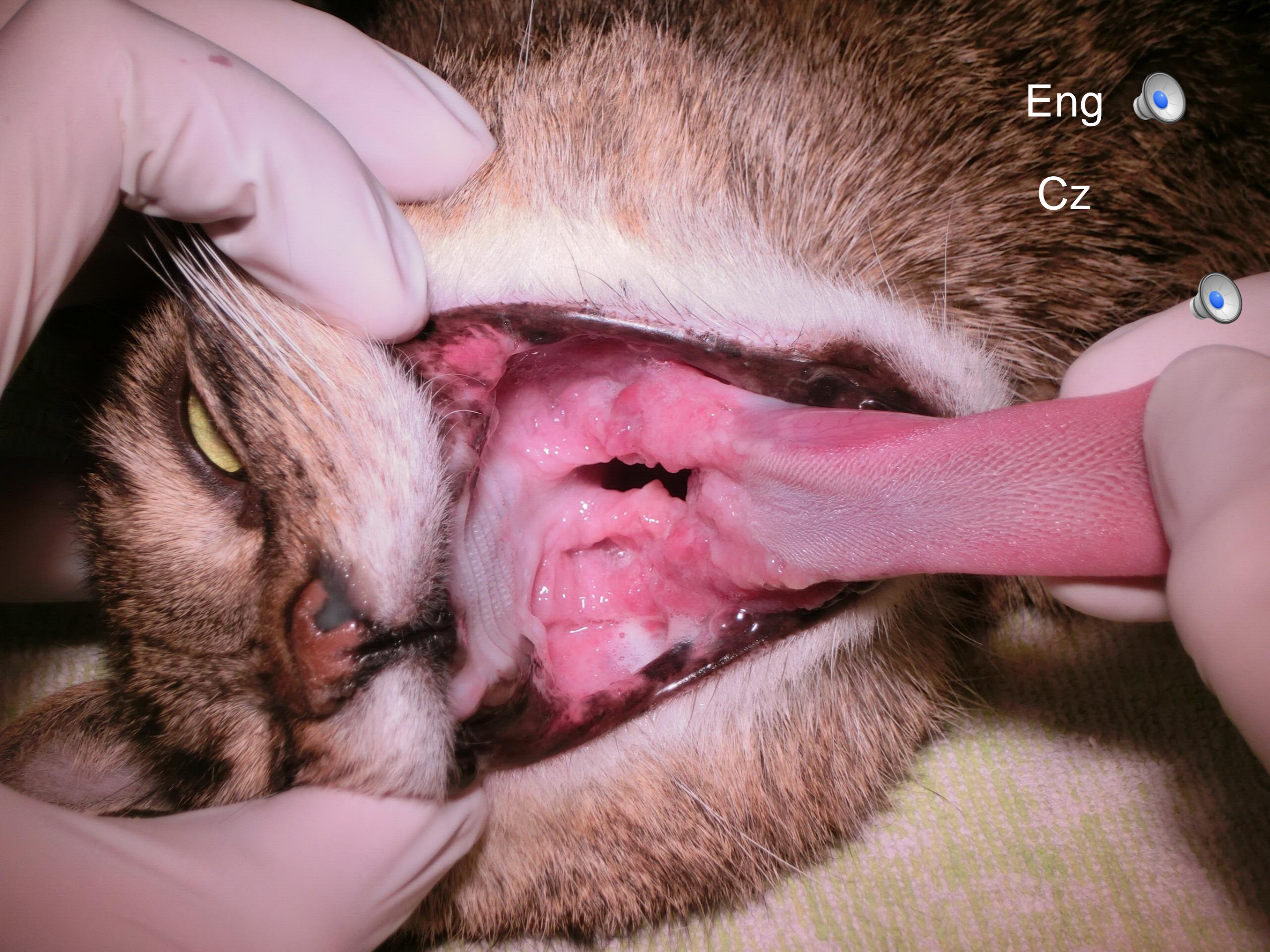

Eng



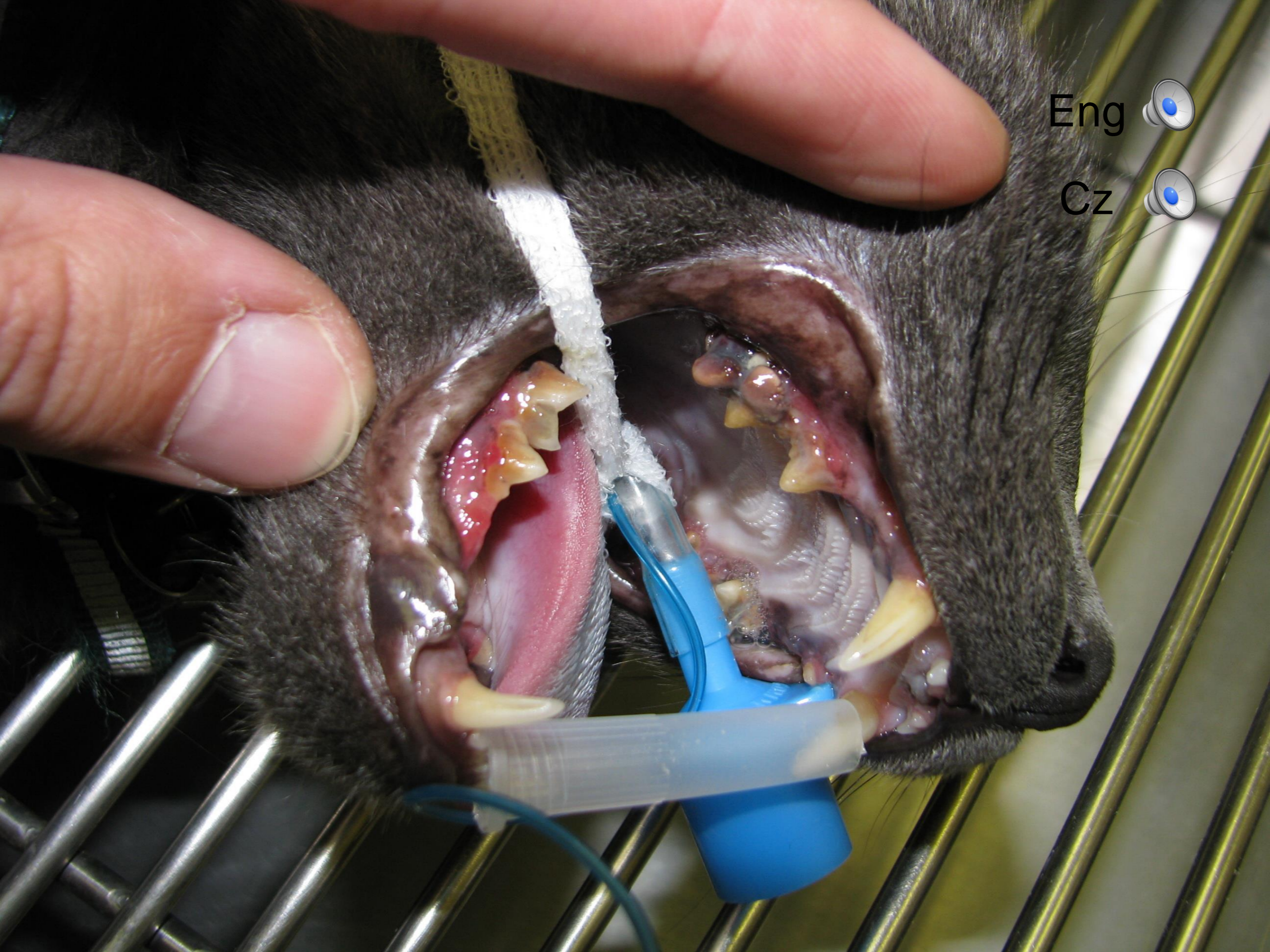Cz





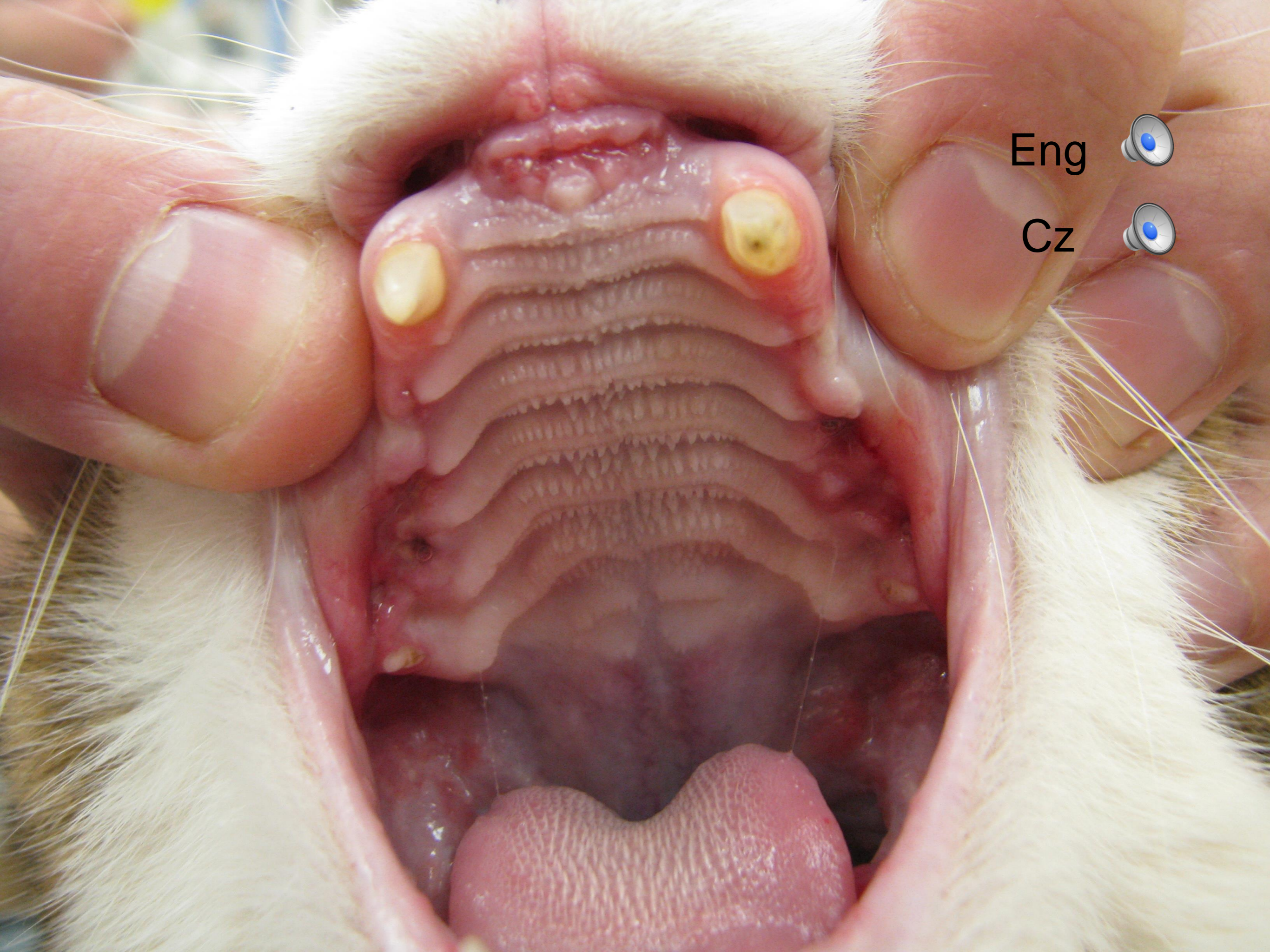Eng 

Cz 



Eng 

Cz 

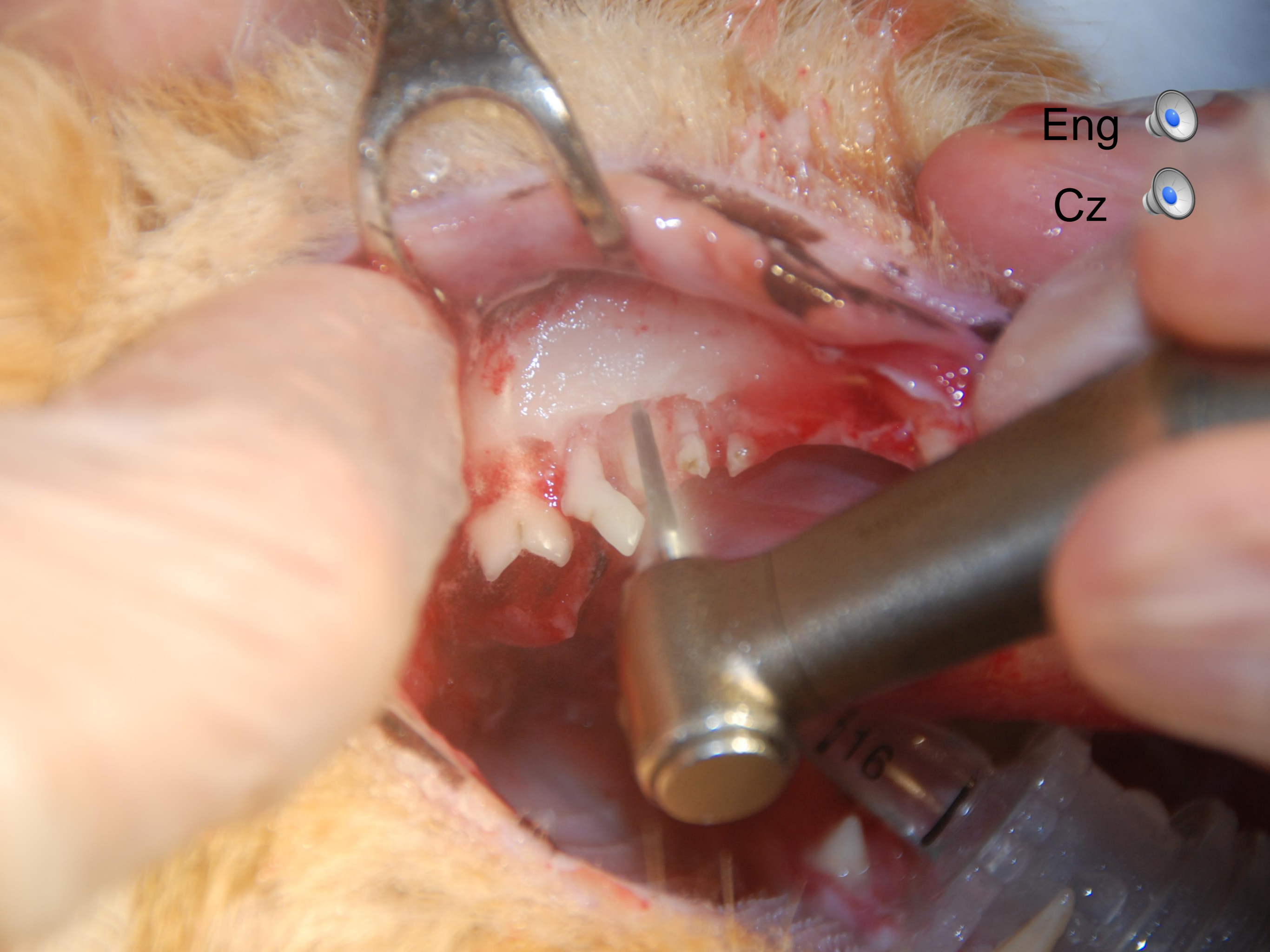


Eng



Cz



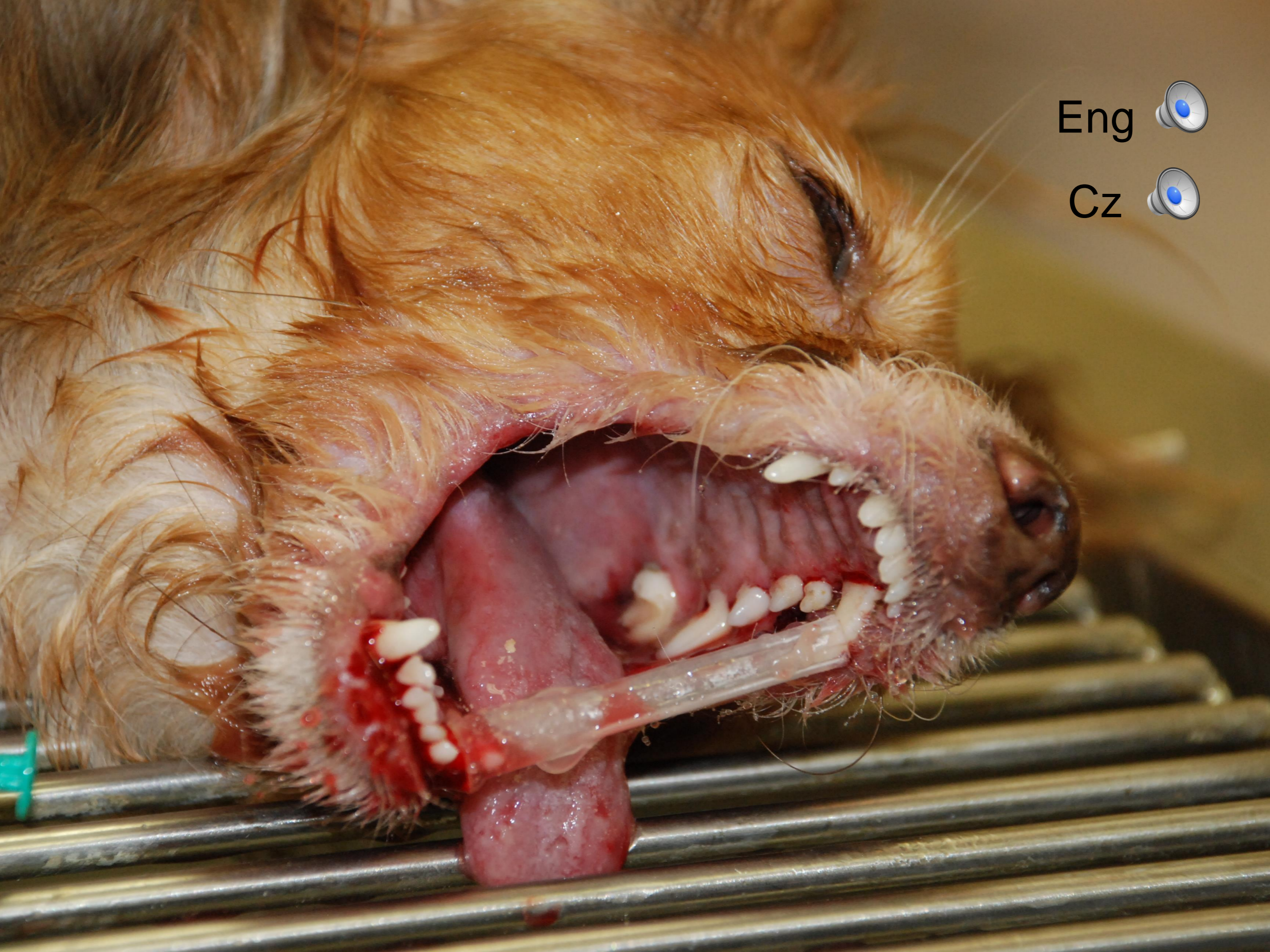

Eng



Cz





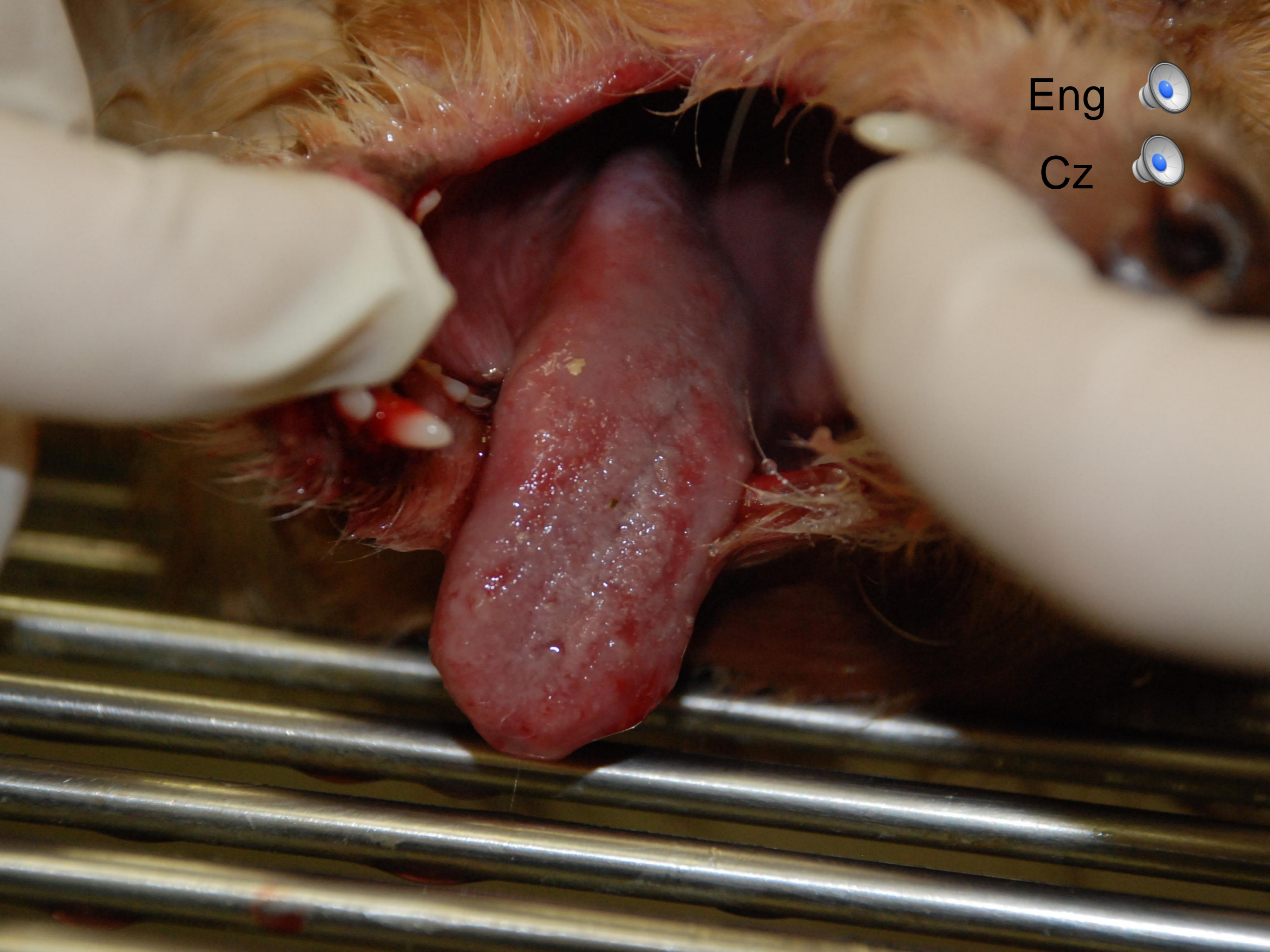
Eng 

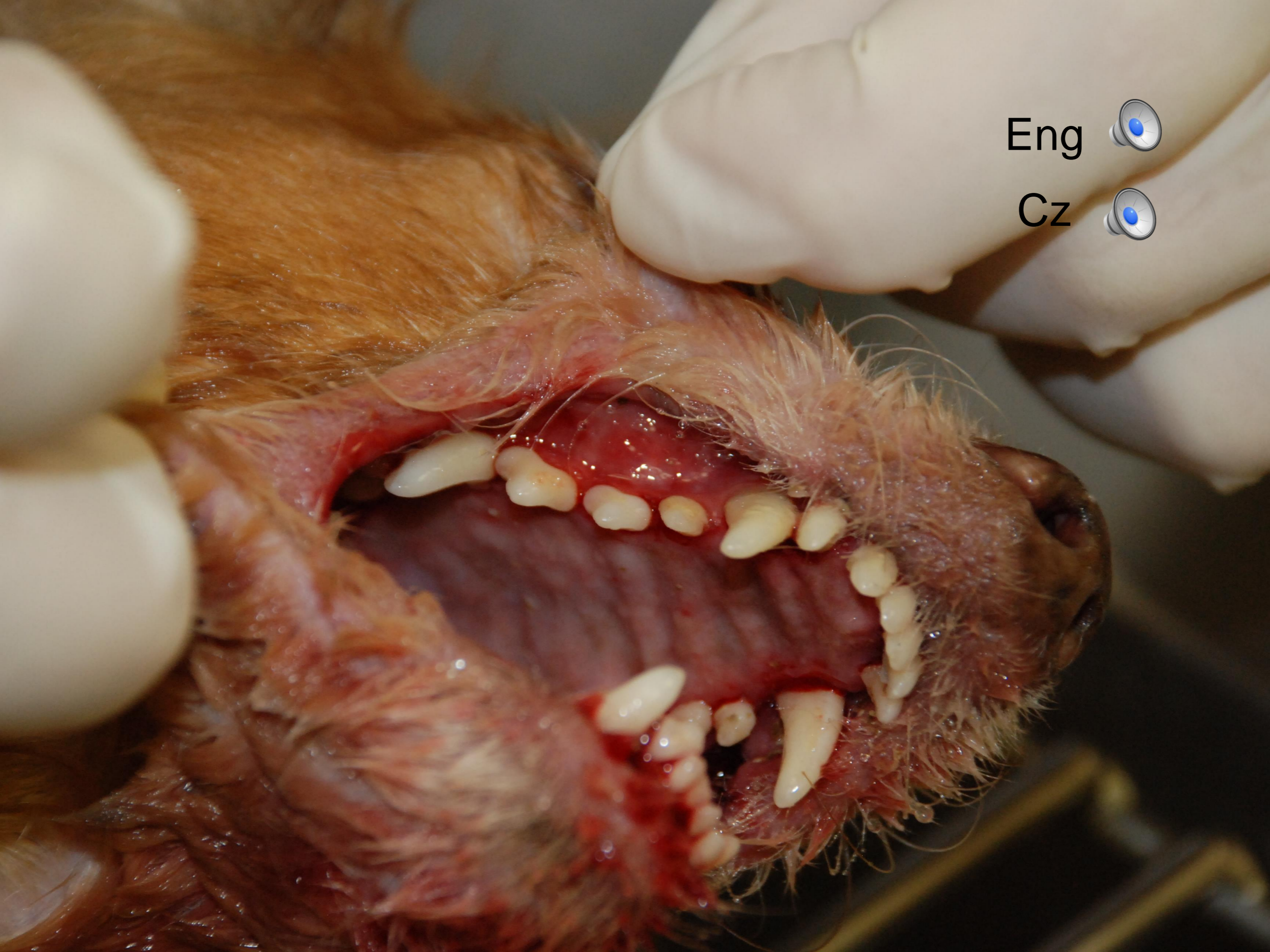Cz 



Eng 

Cz 





Eng



Cz



- Unfortunately there is no preventive measure for gingivostomatitis. Preventive teeth brushing is well accepted by animals without the predisposition , it is less likely to be tolerated by animals prone to the disease , this could be used as an indication and could make the owners seek advice sooner.
- Clinical signs include behavioural changes, anorexia inappetence, excessive salivation and halitosis, pawing at the mouth, lack of grooming cats.

**ORL**

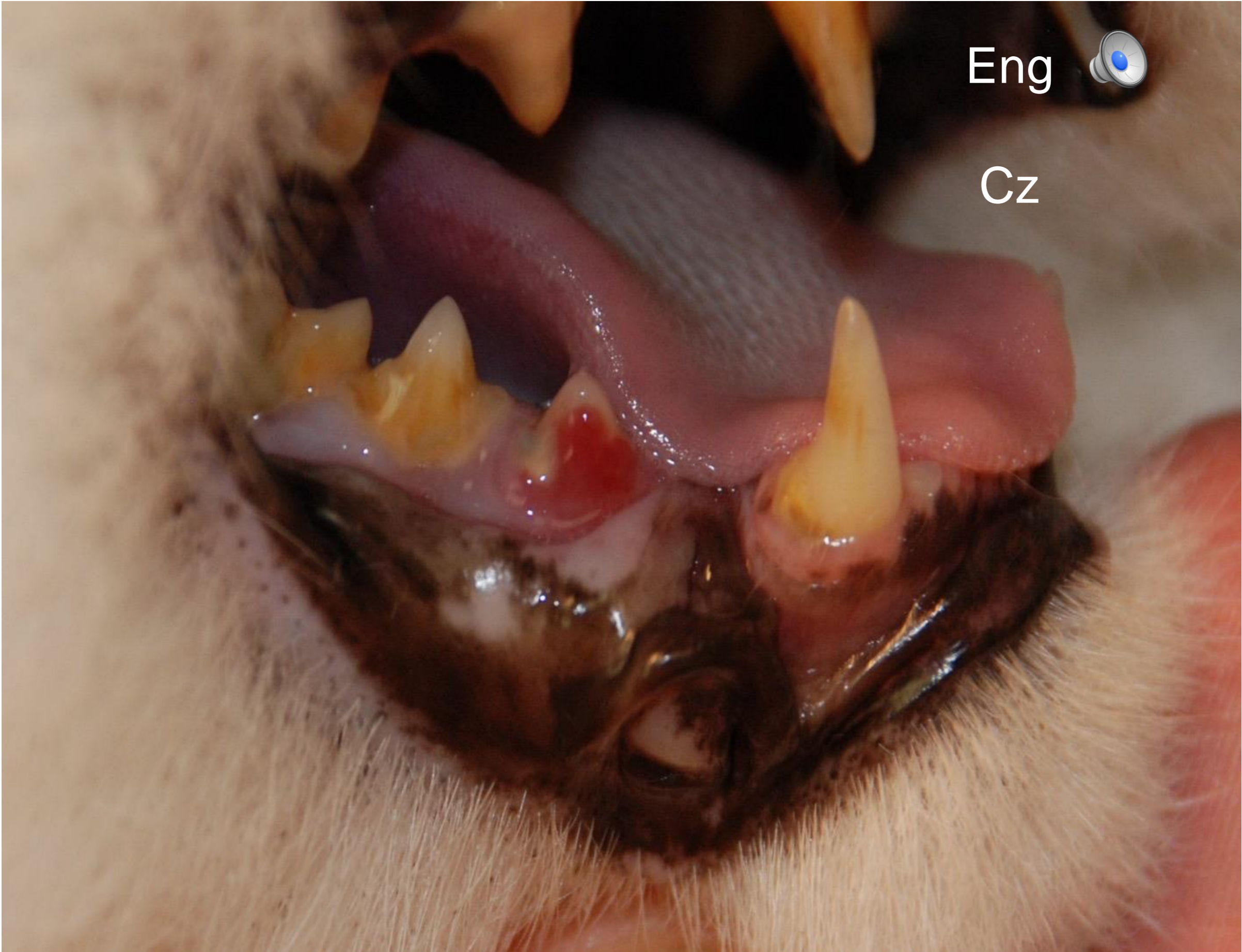Eng 

Cz 

Eng



Cz



Eng



Cz



Eng



Cz



# GINGIVAL HYPERPLASIA

Cz 

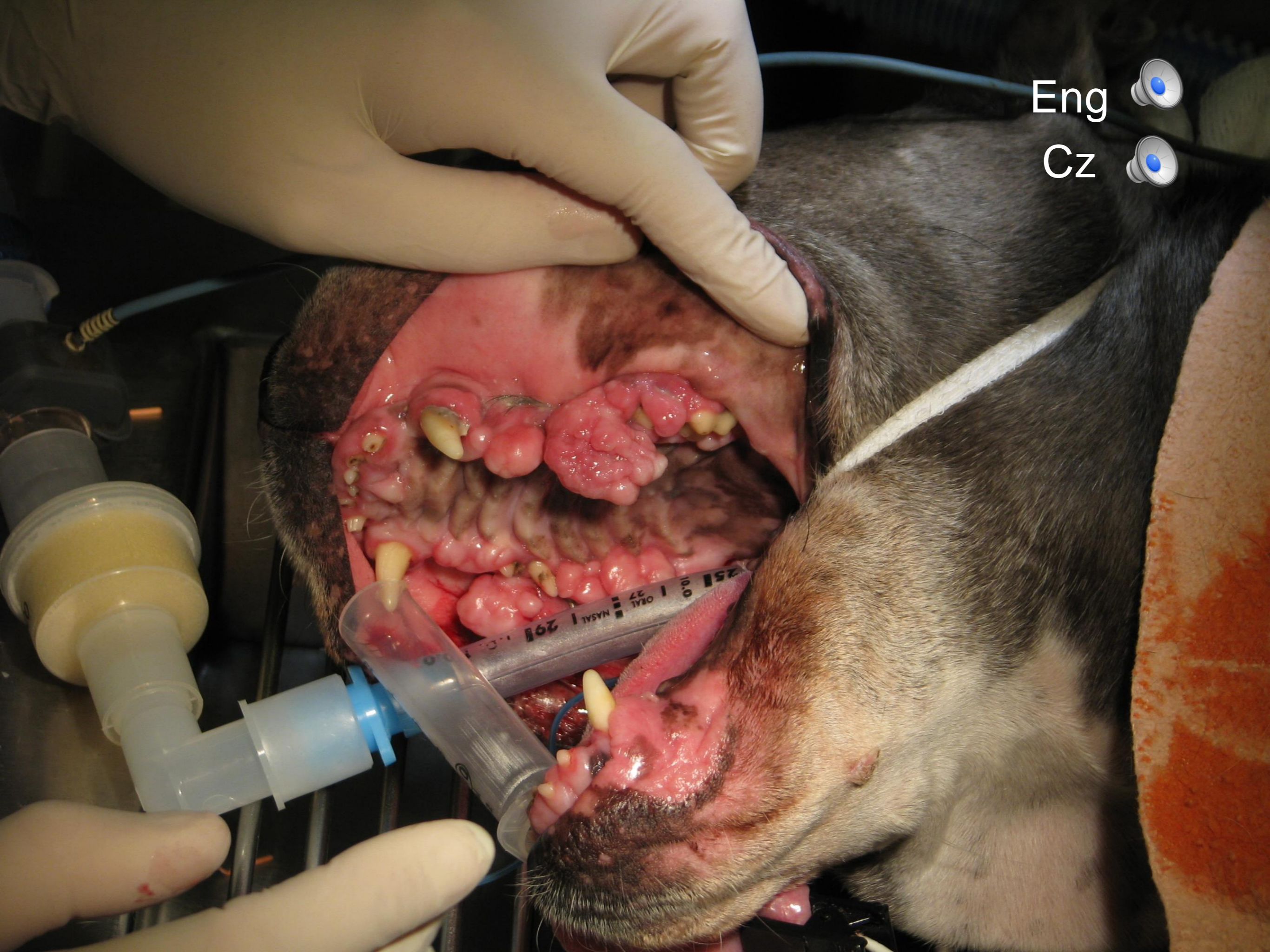Eng 

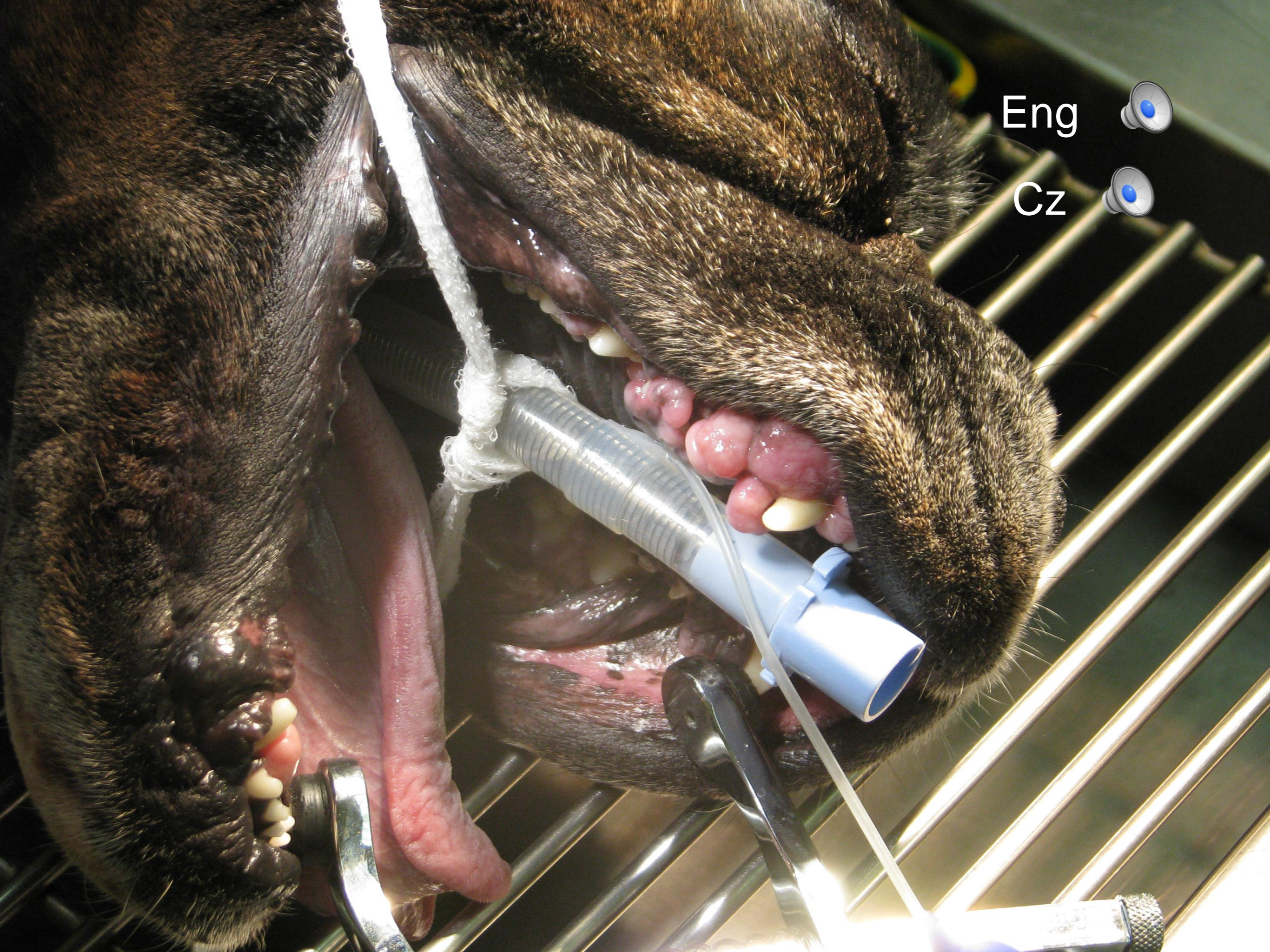

Eng



Cz



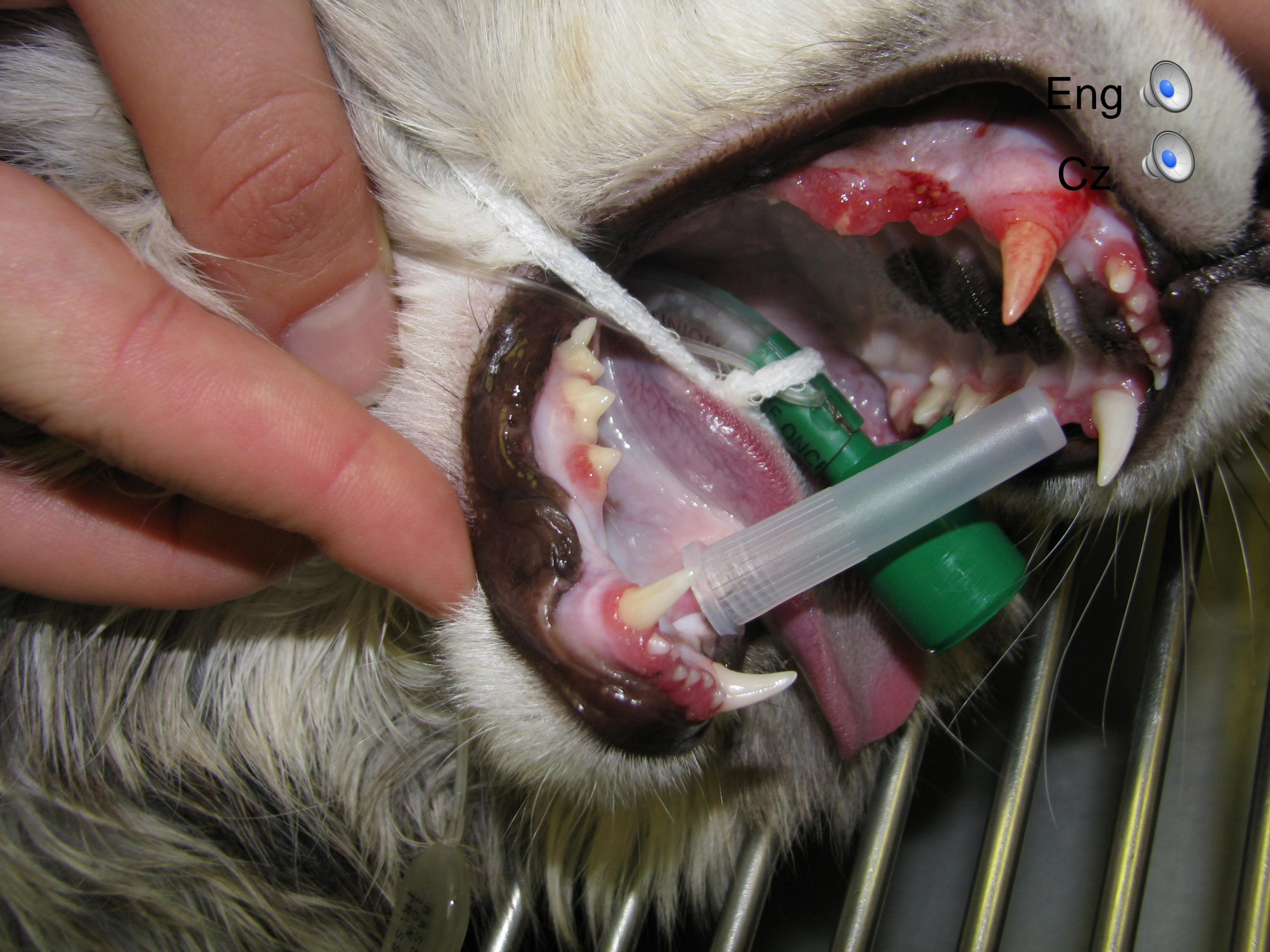

Eng



Cz



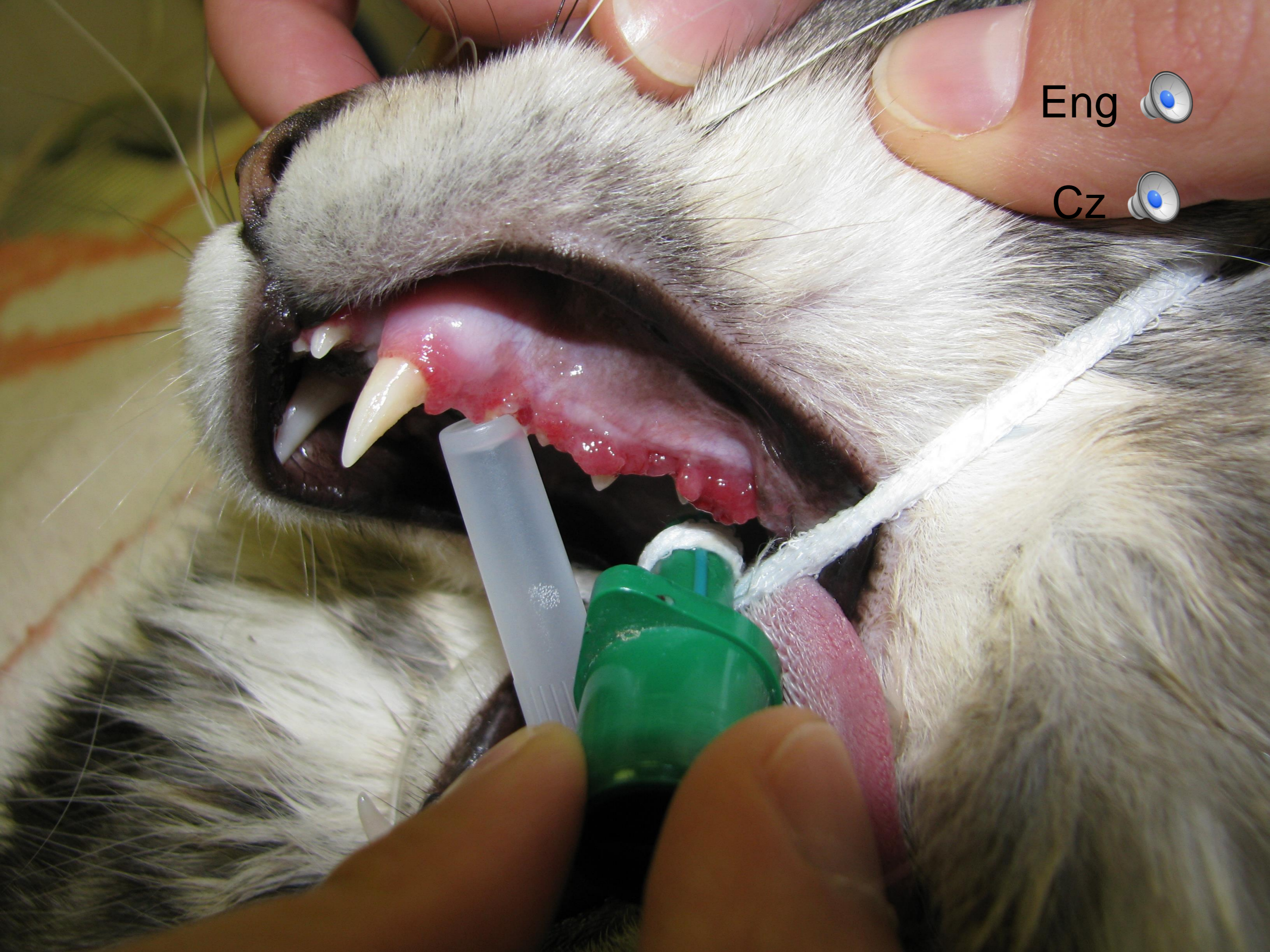


Eng 

Cz 

Eng 

Cz 



# Oncological Surgery

Eng 

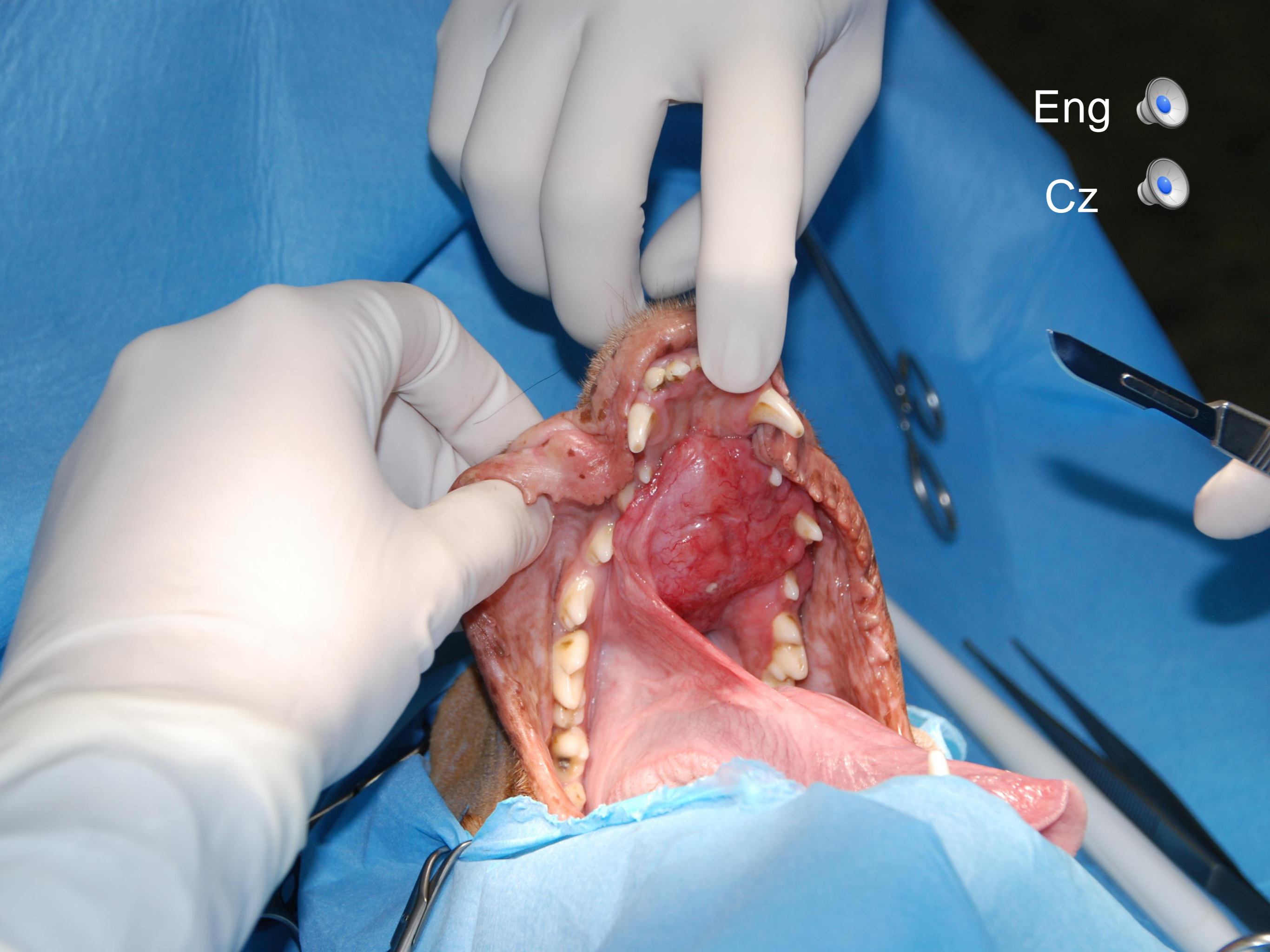
Cz 

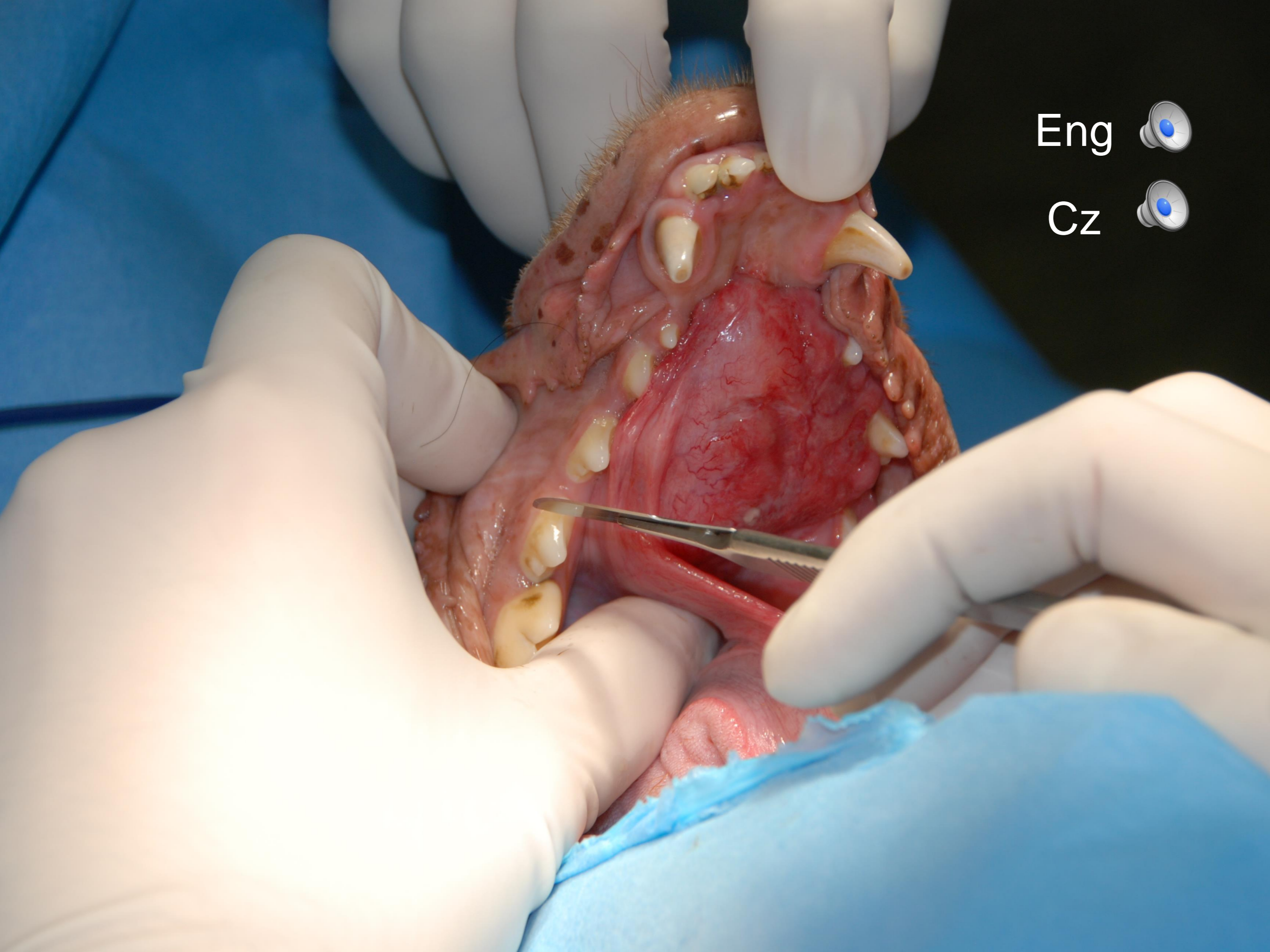


Eng



Cz



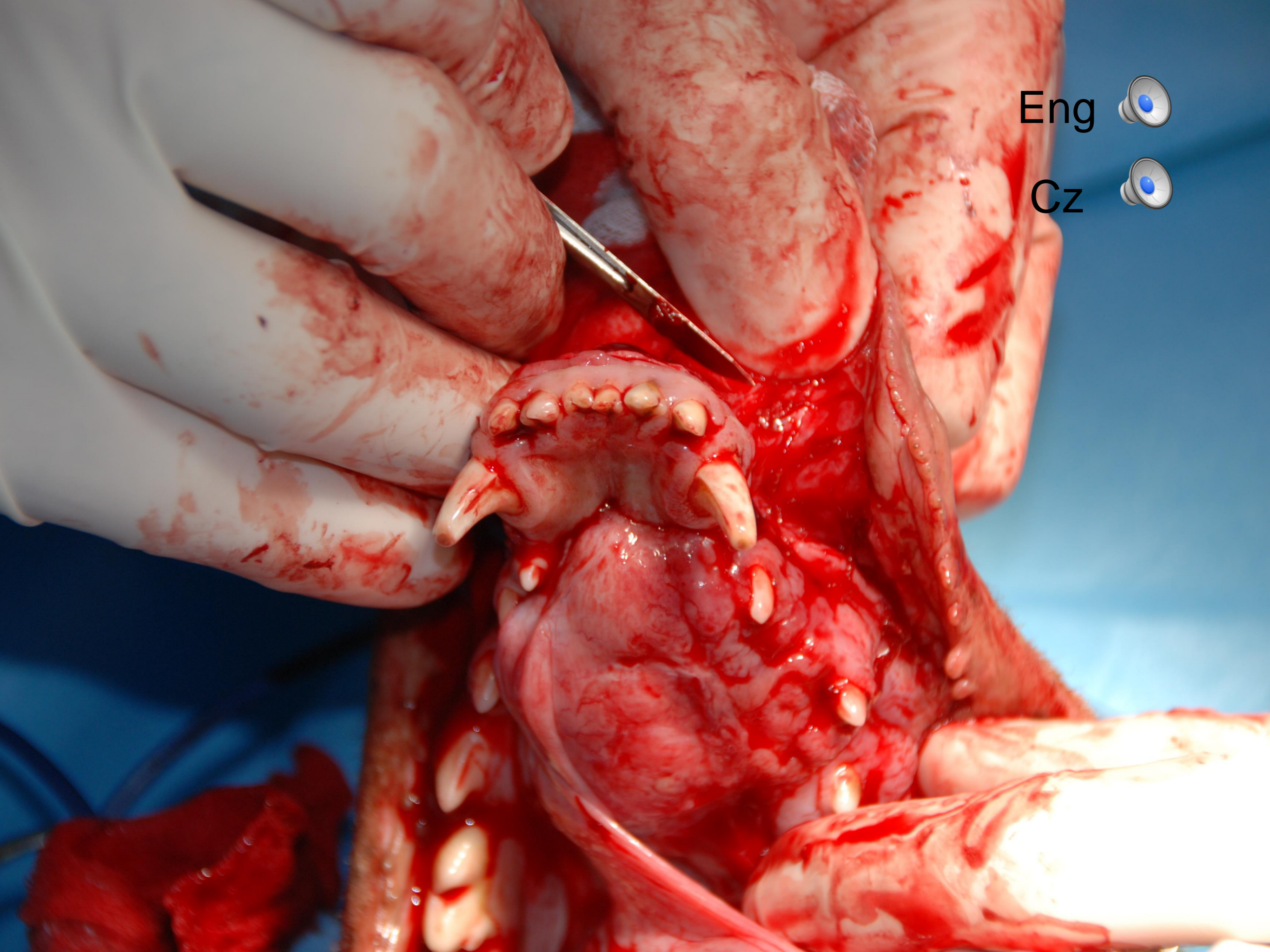



Eng



Cz





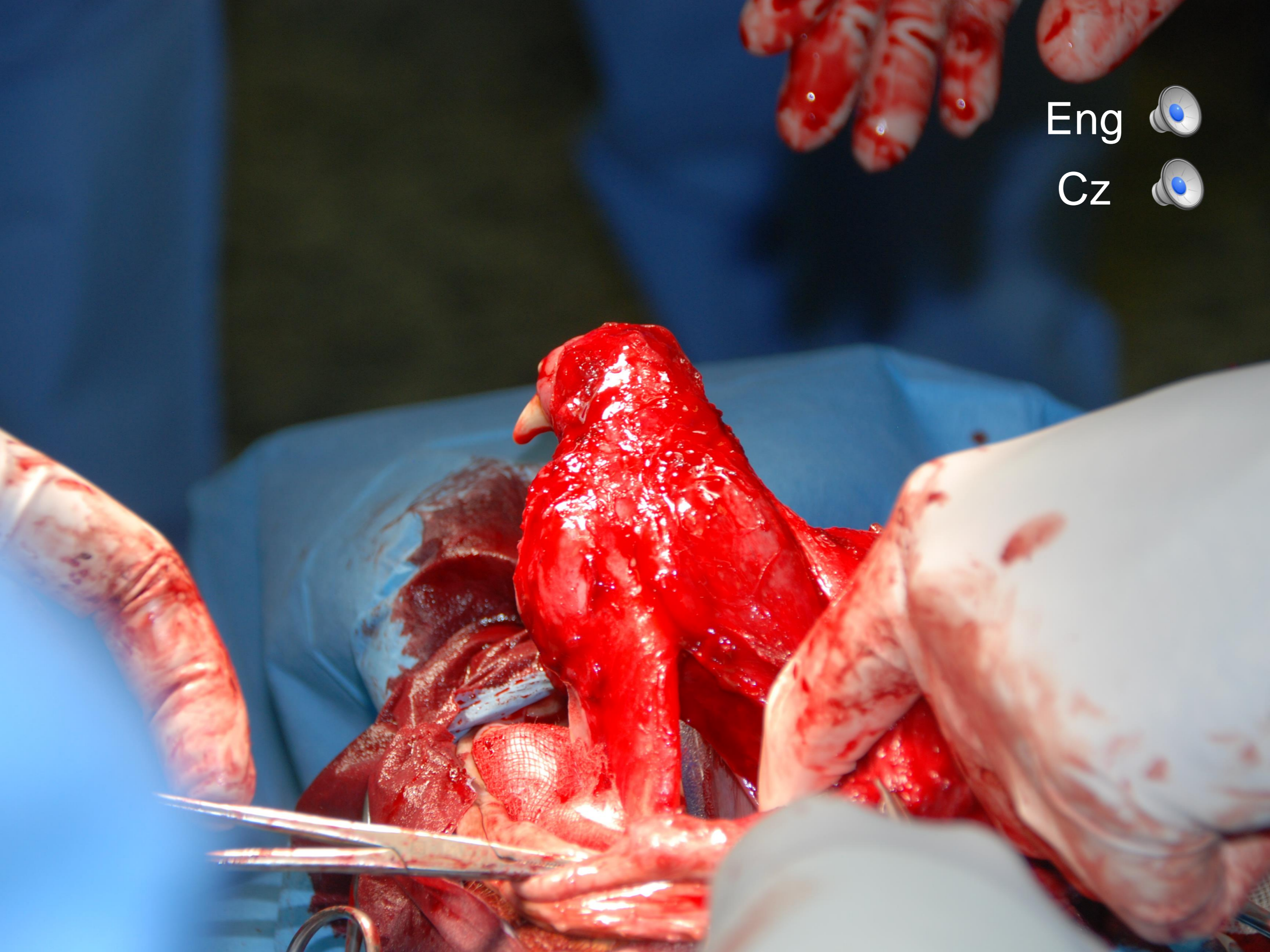


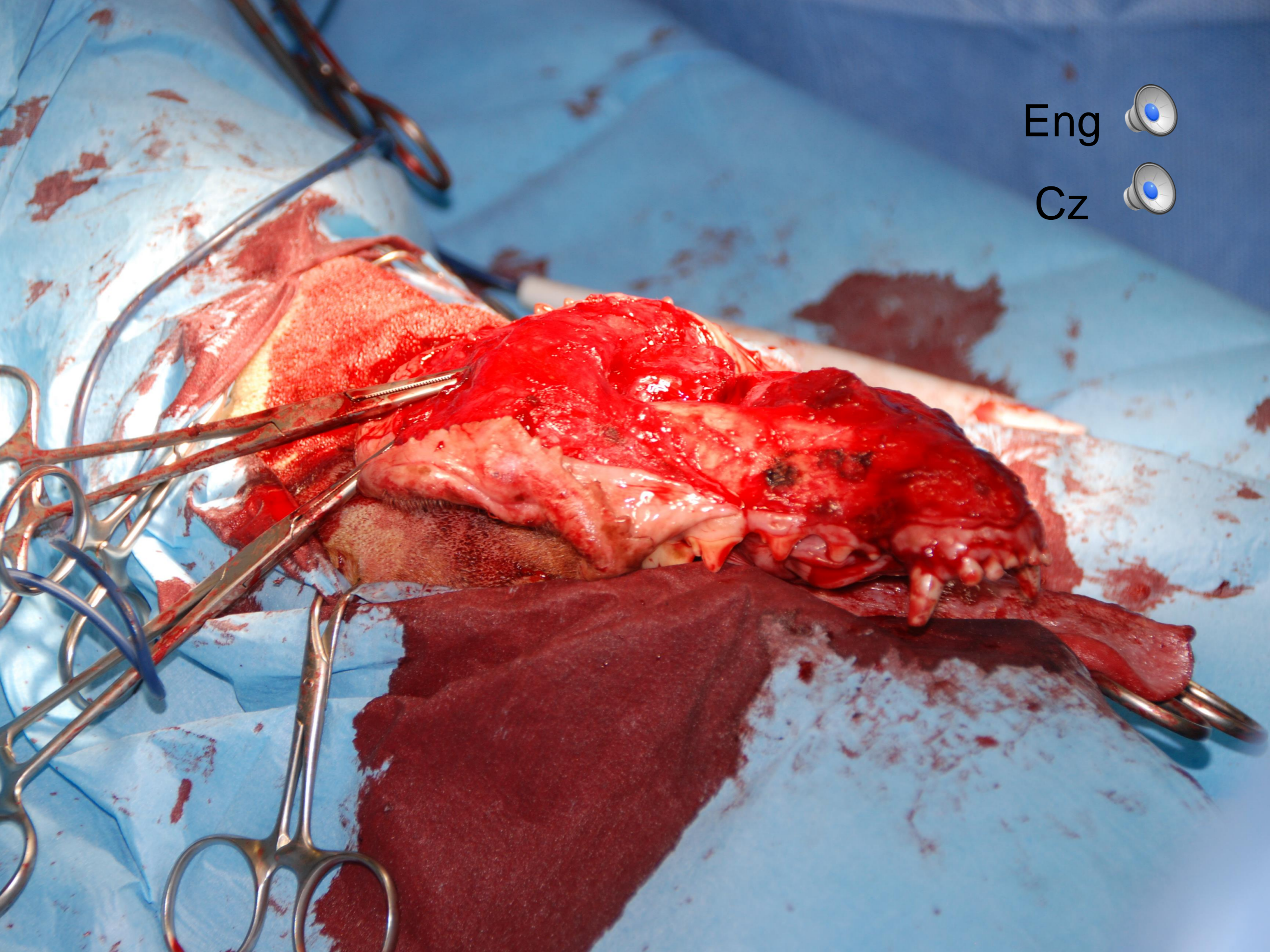
Eng 

Cz 



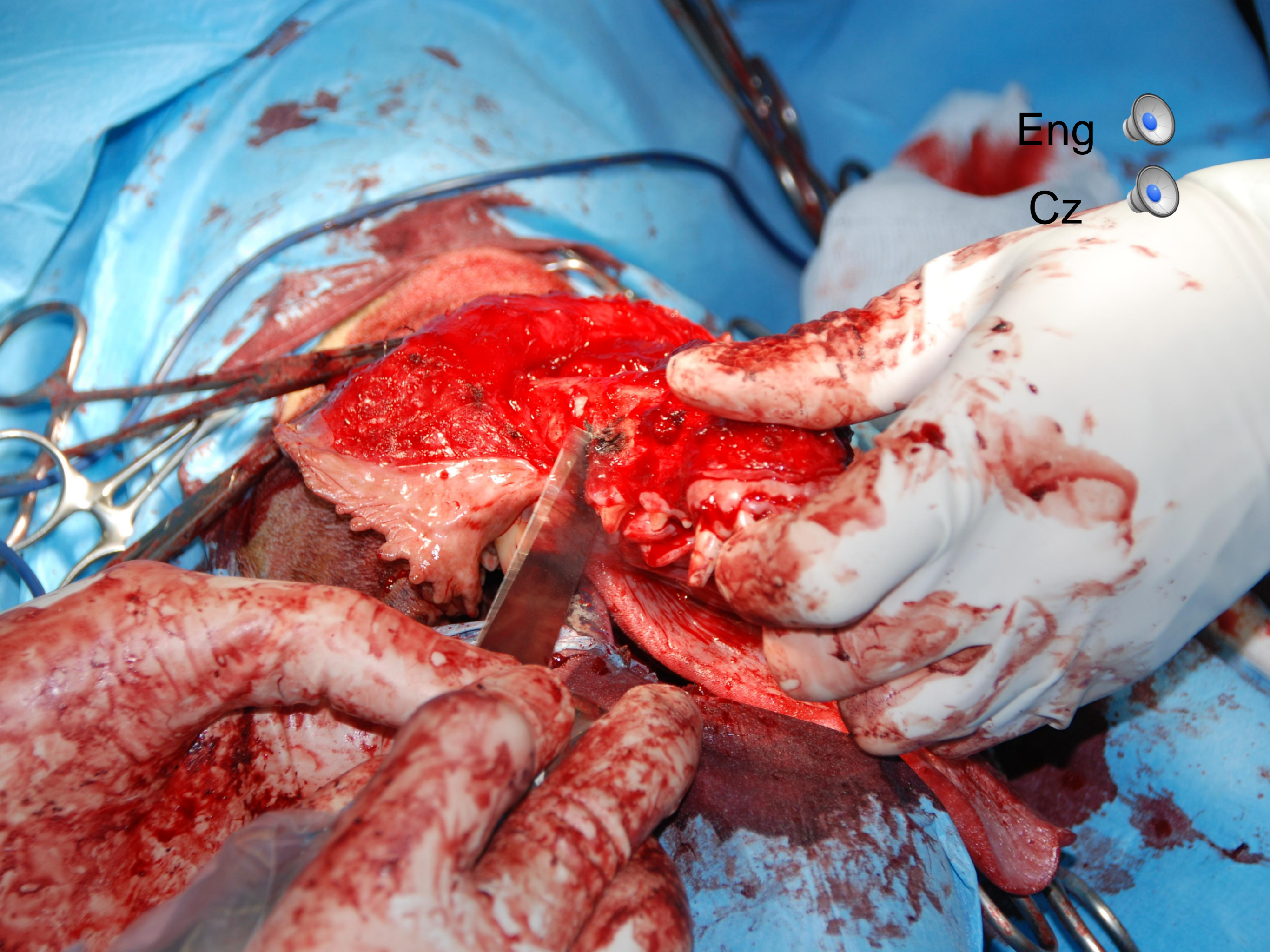
Eng   
Cz 





Eng 

Cz 



Eng



Cz



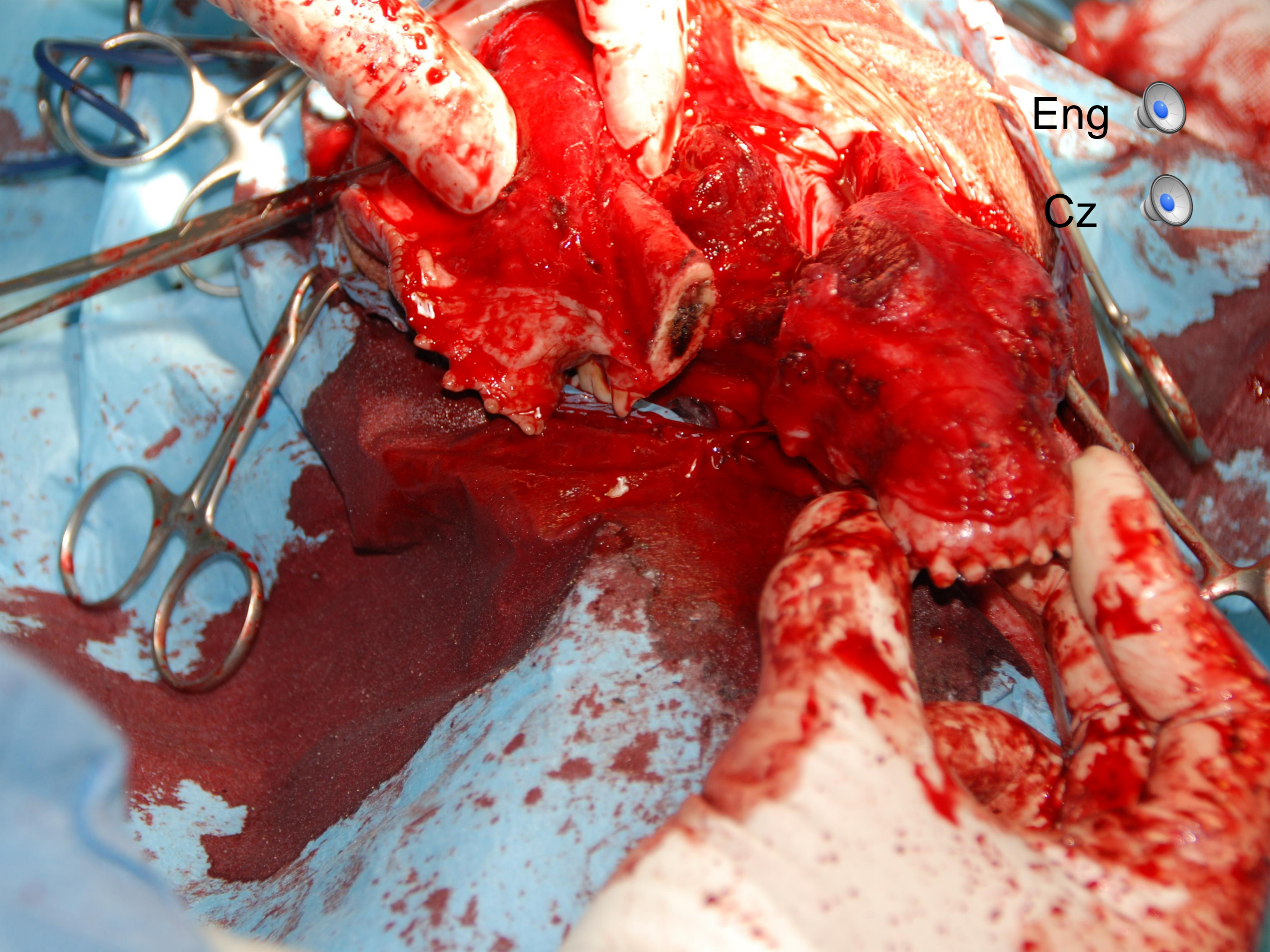


Eng



Cz





Eng

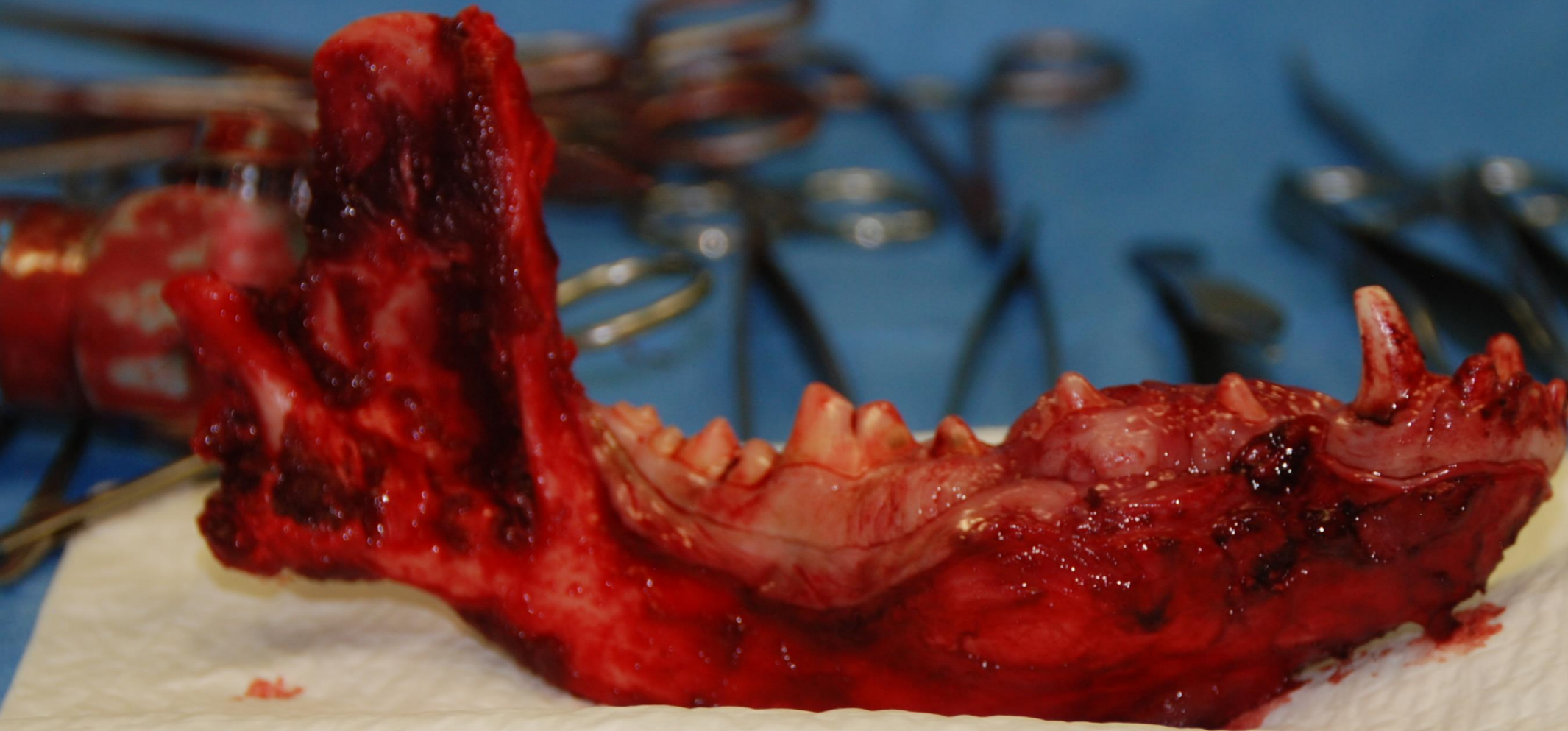


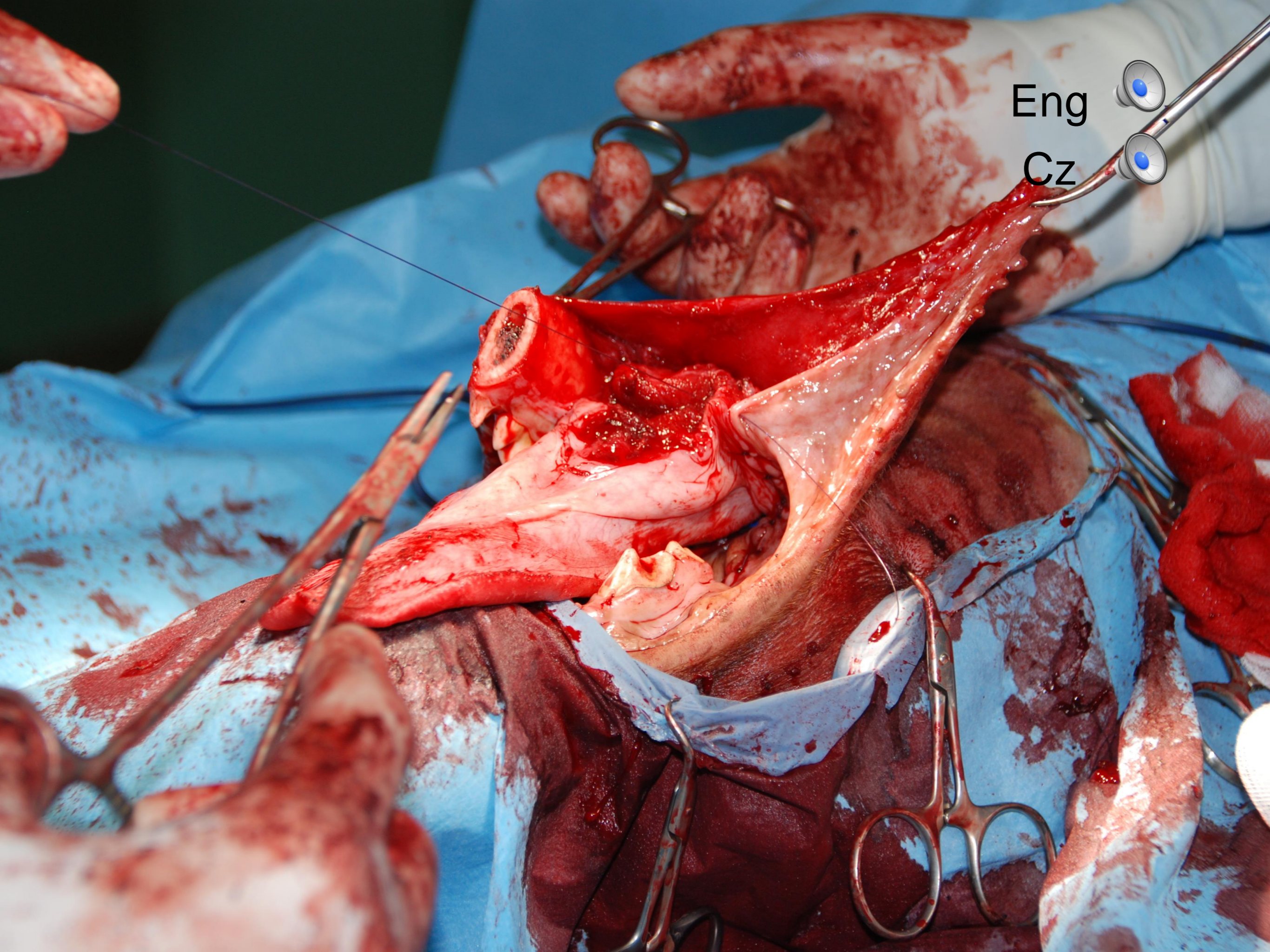
Cz



Eng 

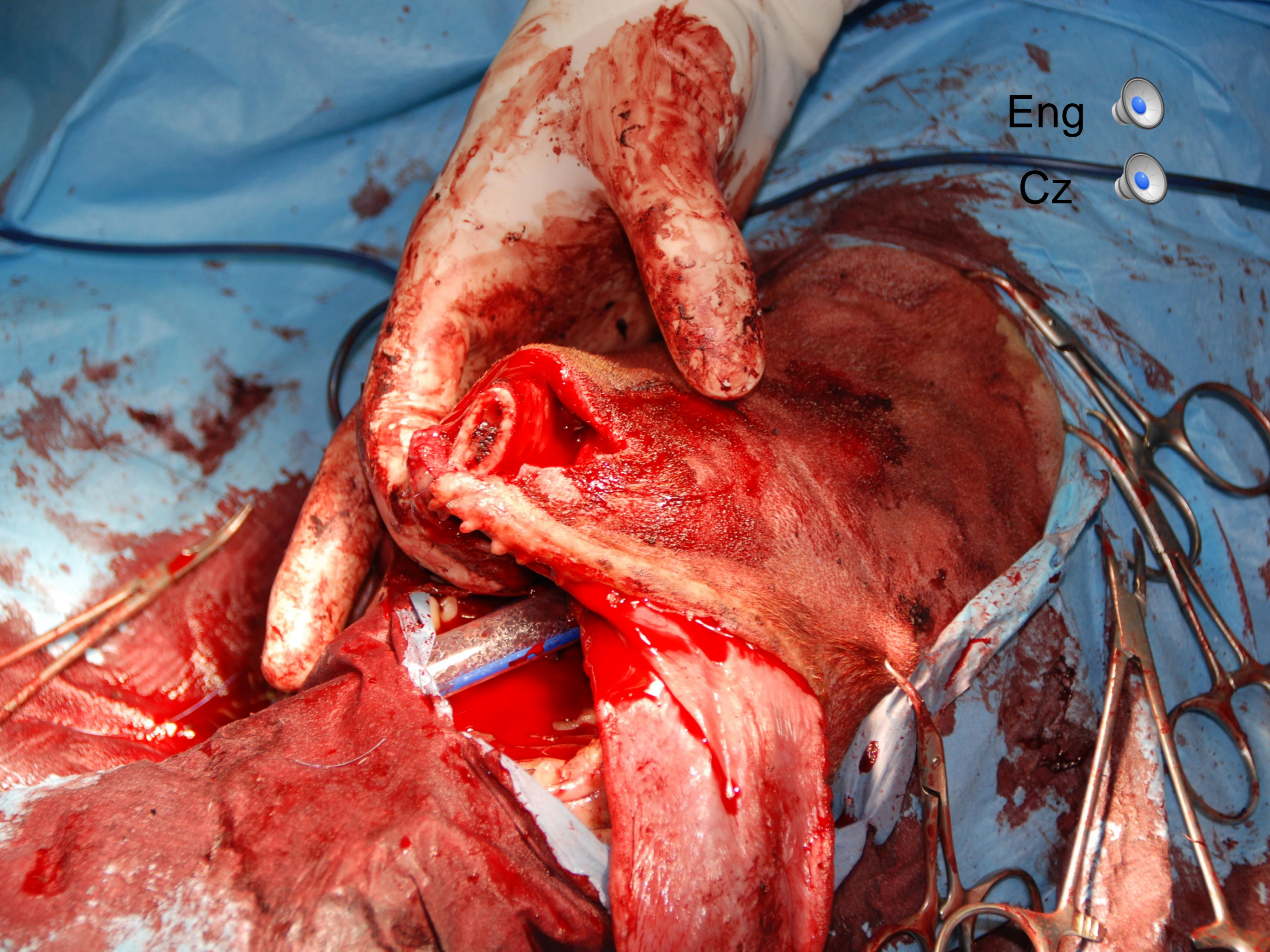
Cz 





Eng

Cz



Eng



Cz

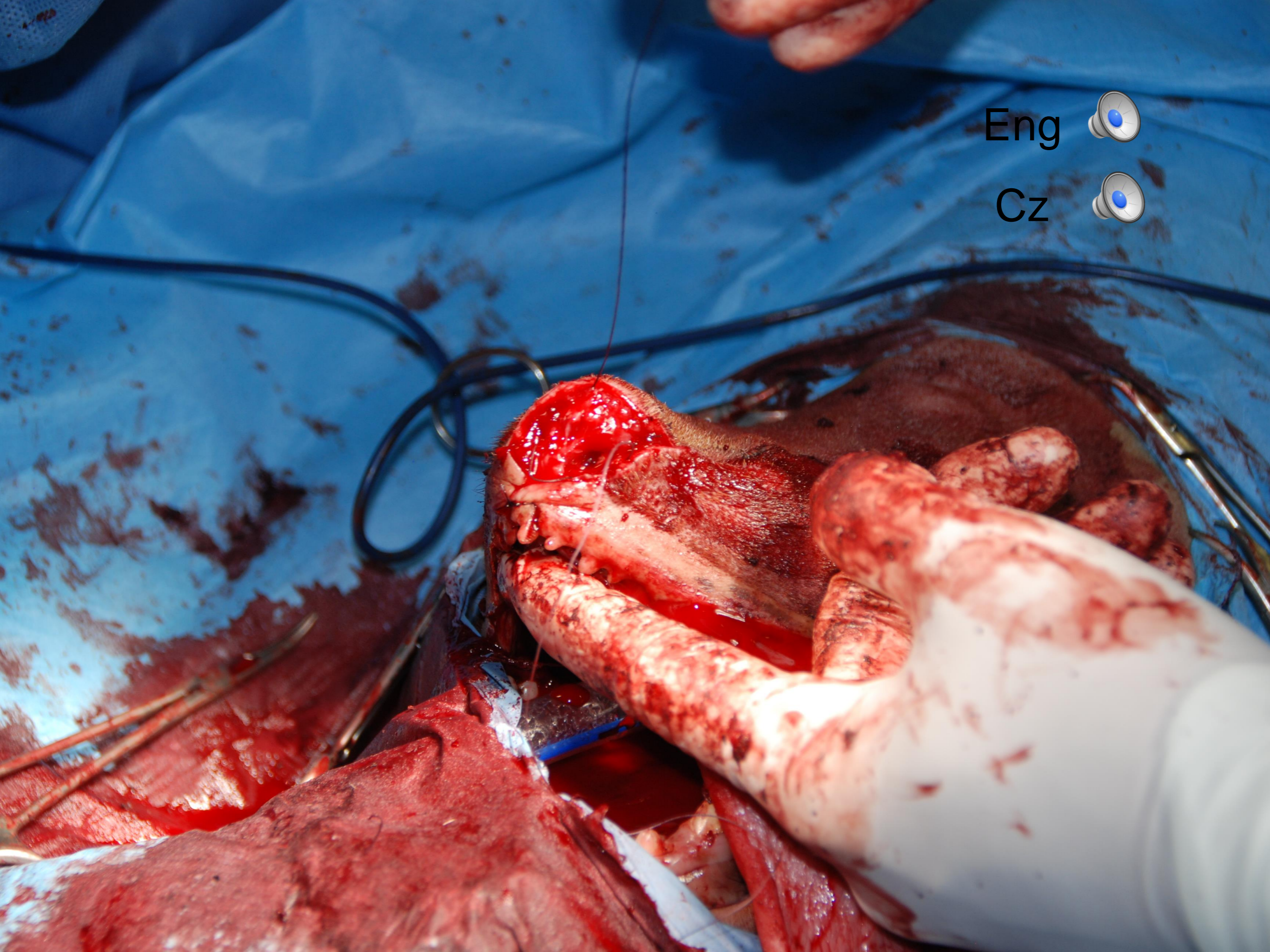


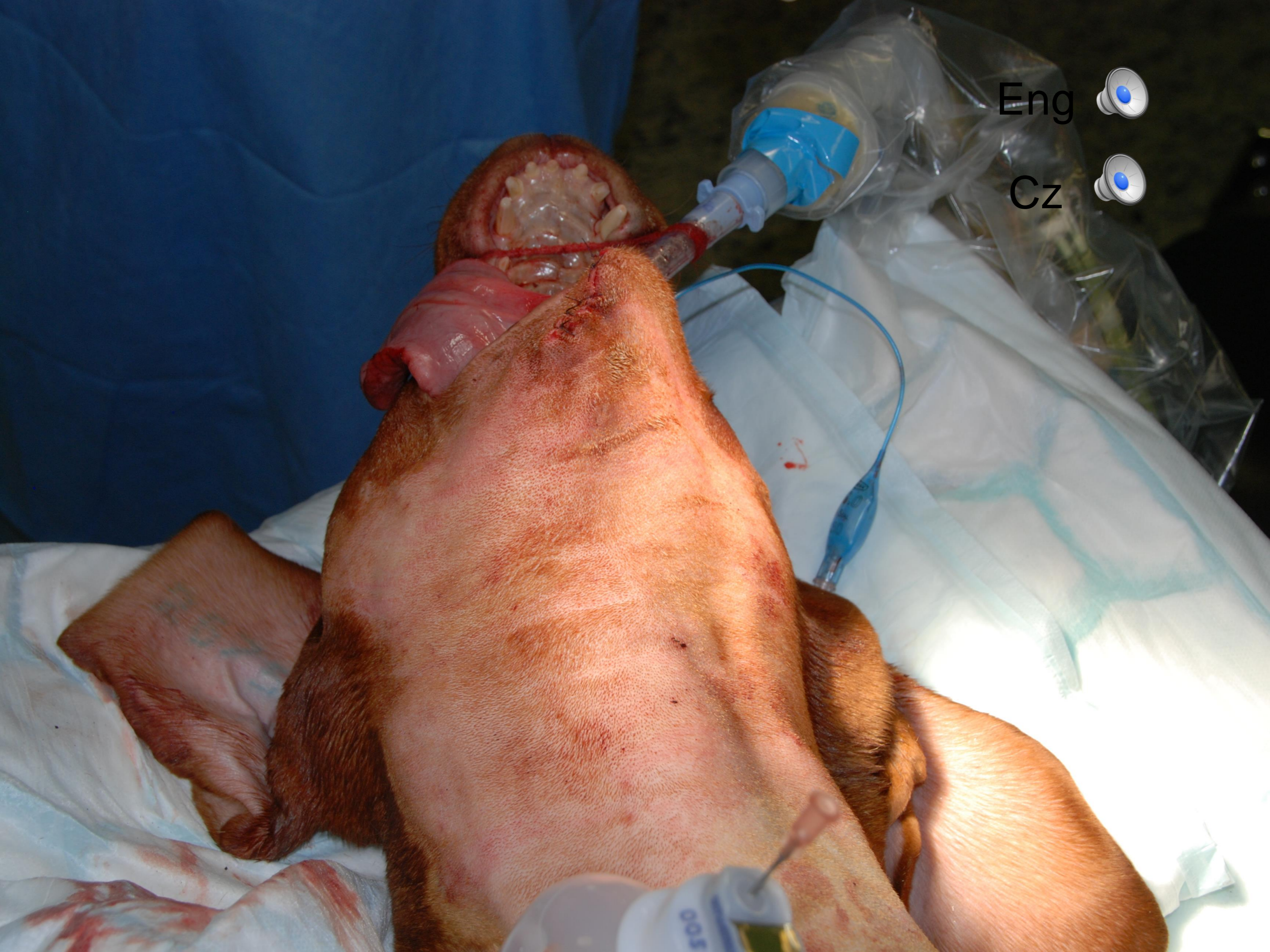

Eng



Cz





Eng



Cz





Eng



Cz

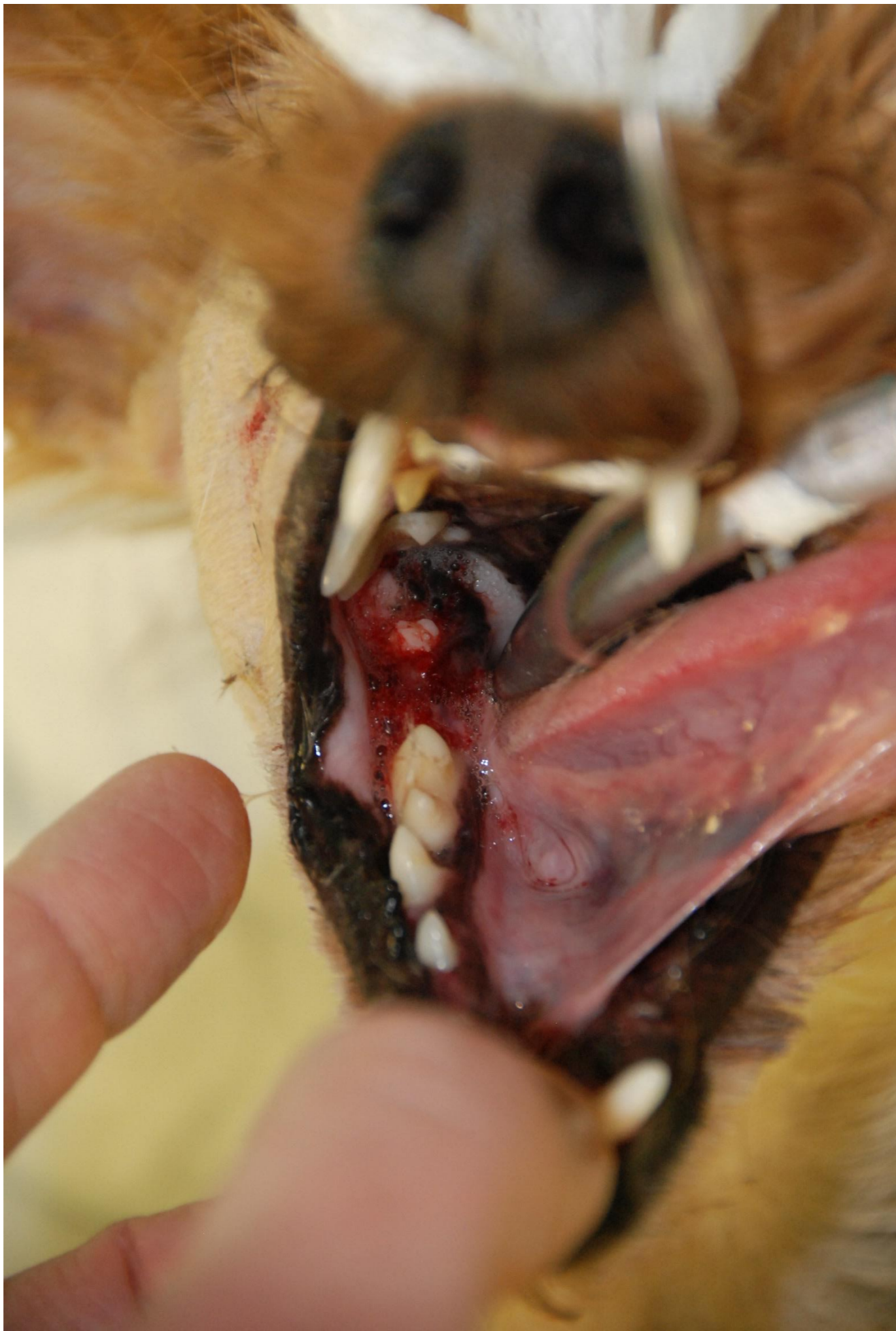

Eng 

Cz 

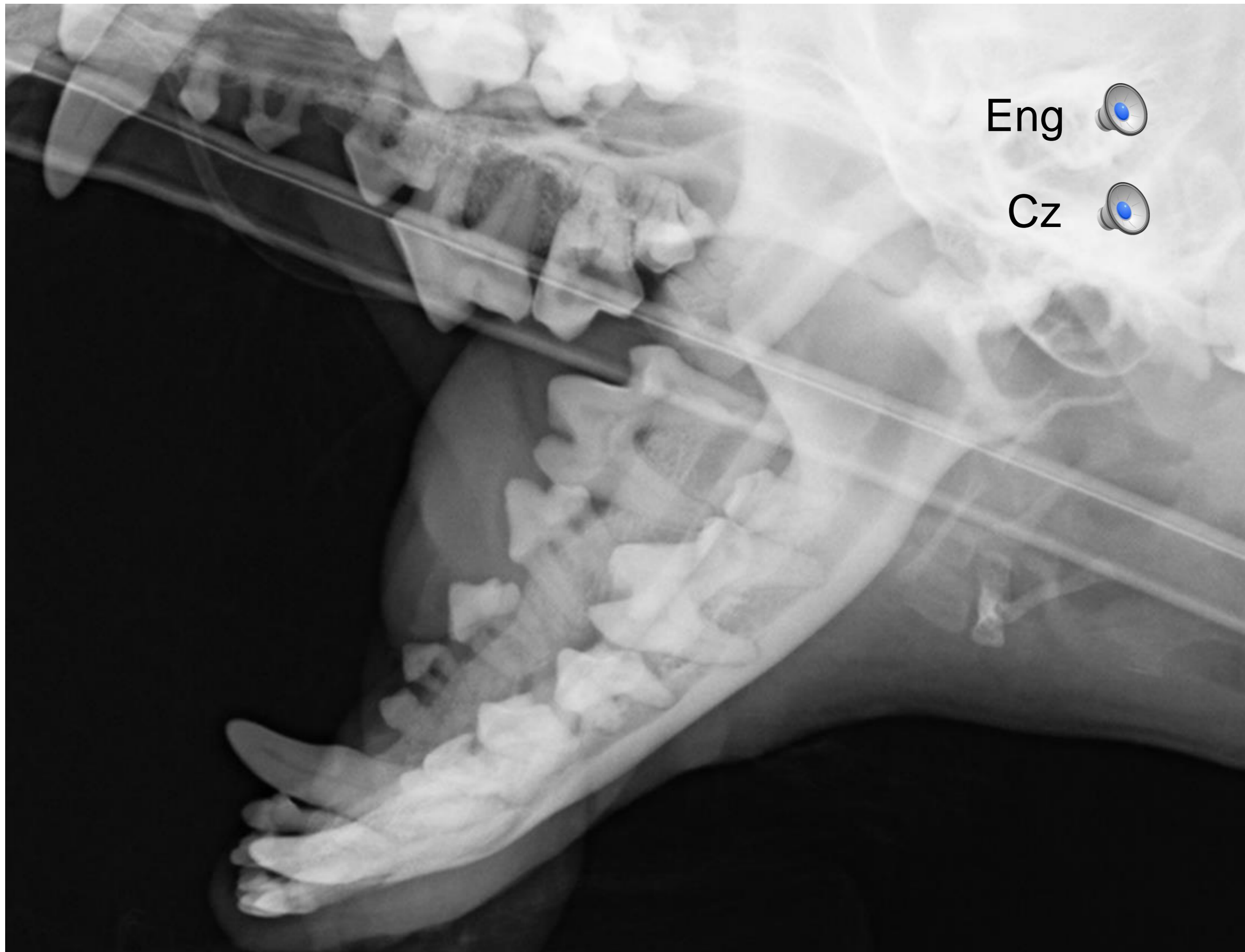


Trauma



Eng 

Cz 

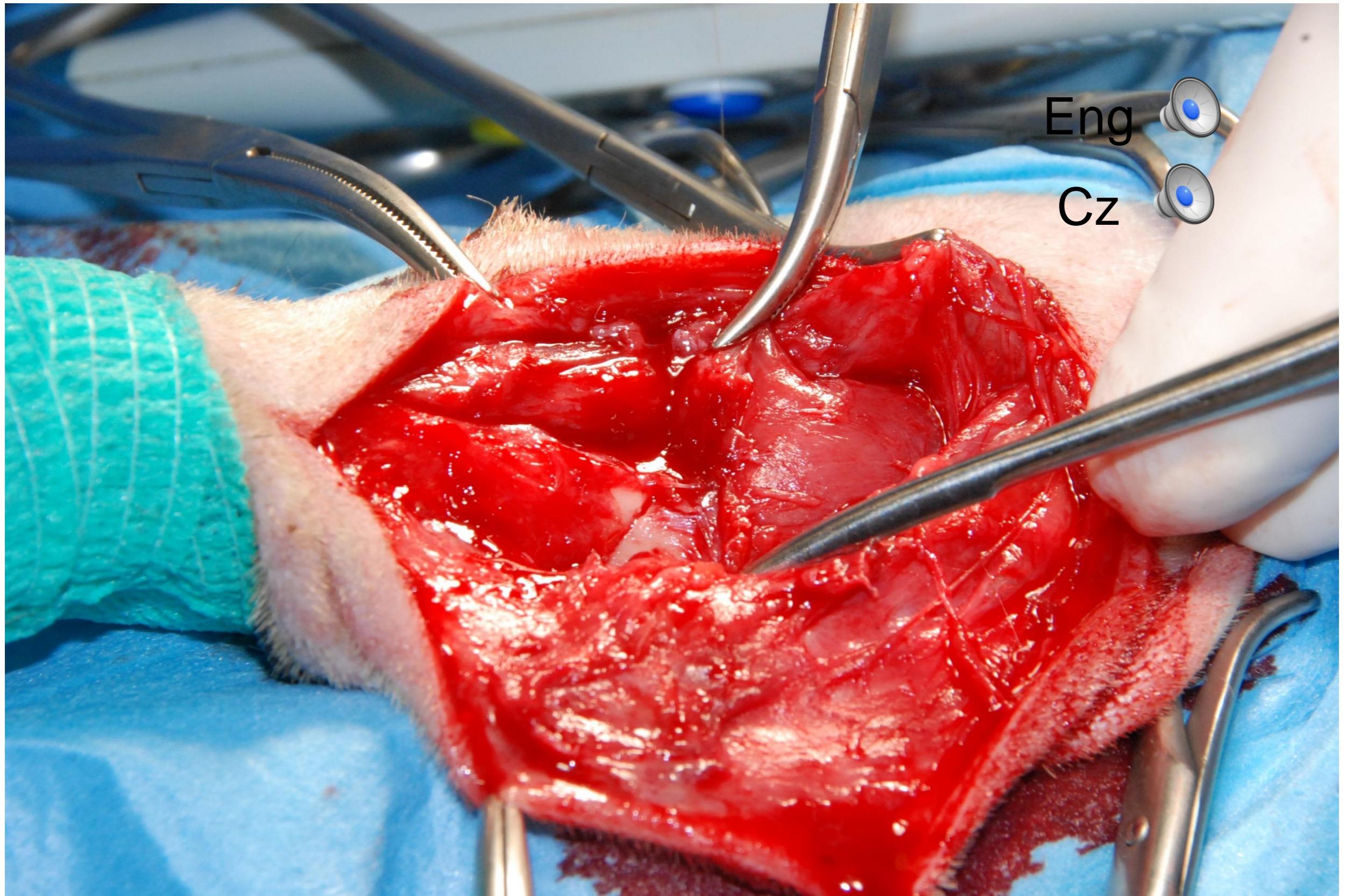


Eng



Cz



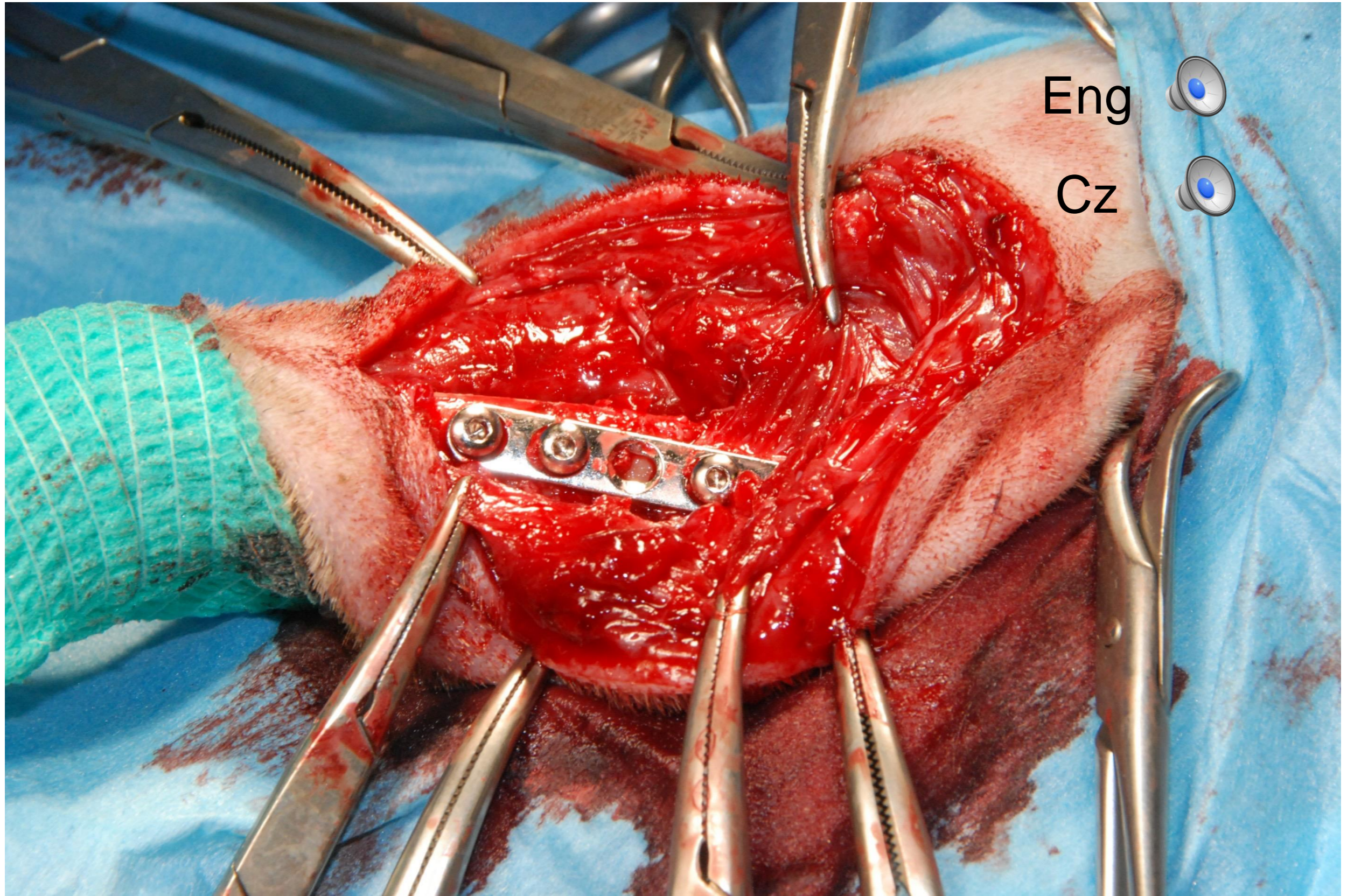


Eng



Cz





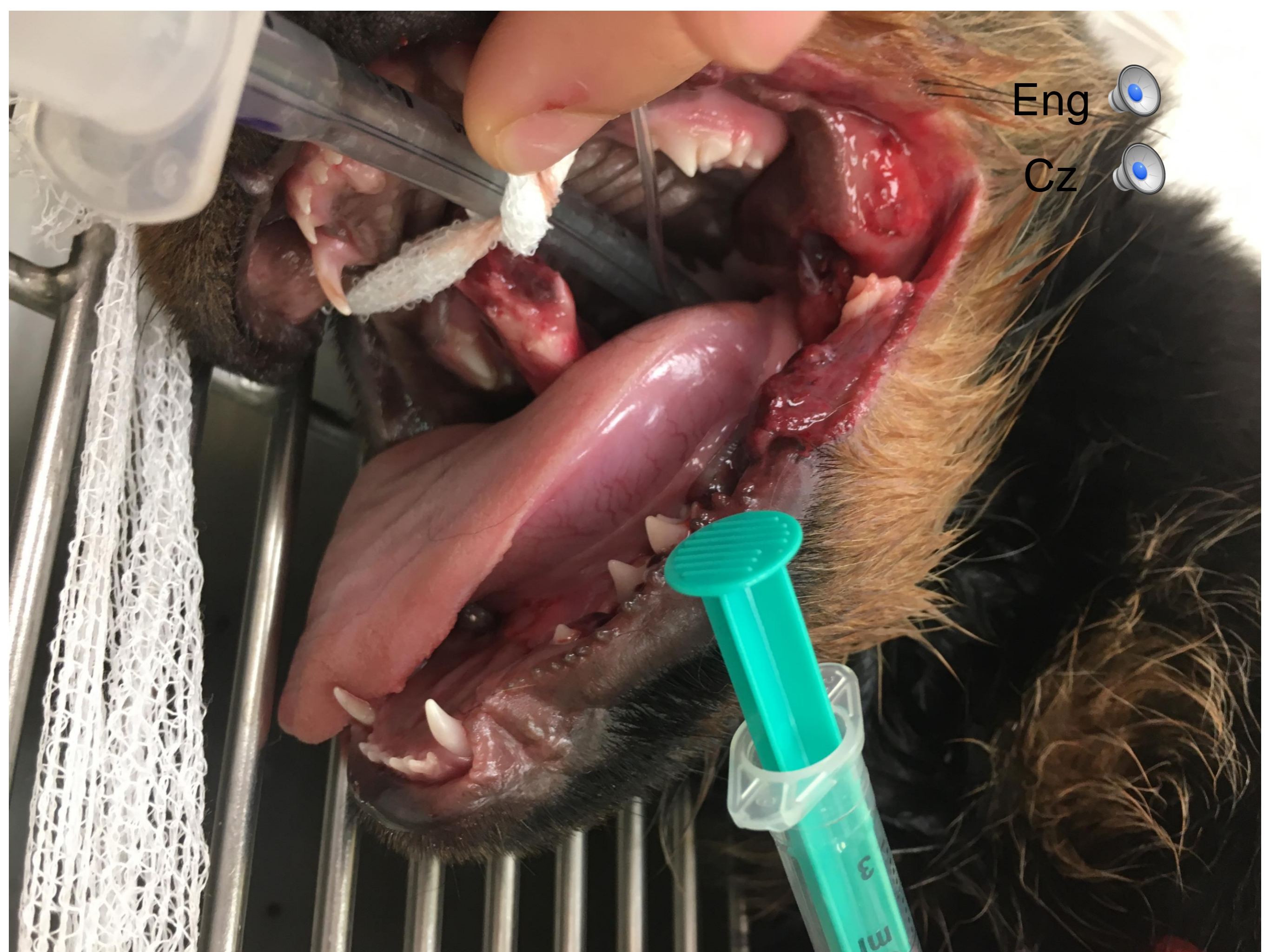
Eng



Cz





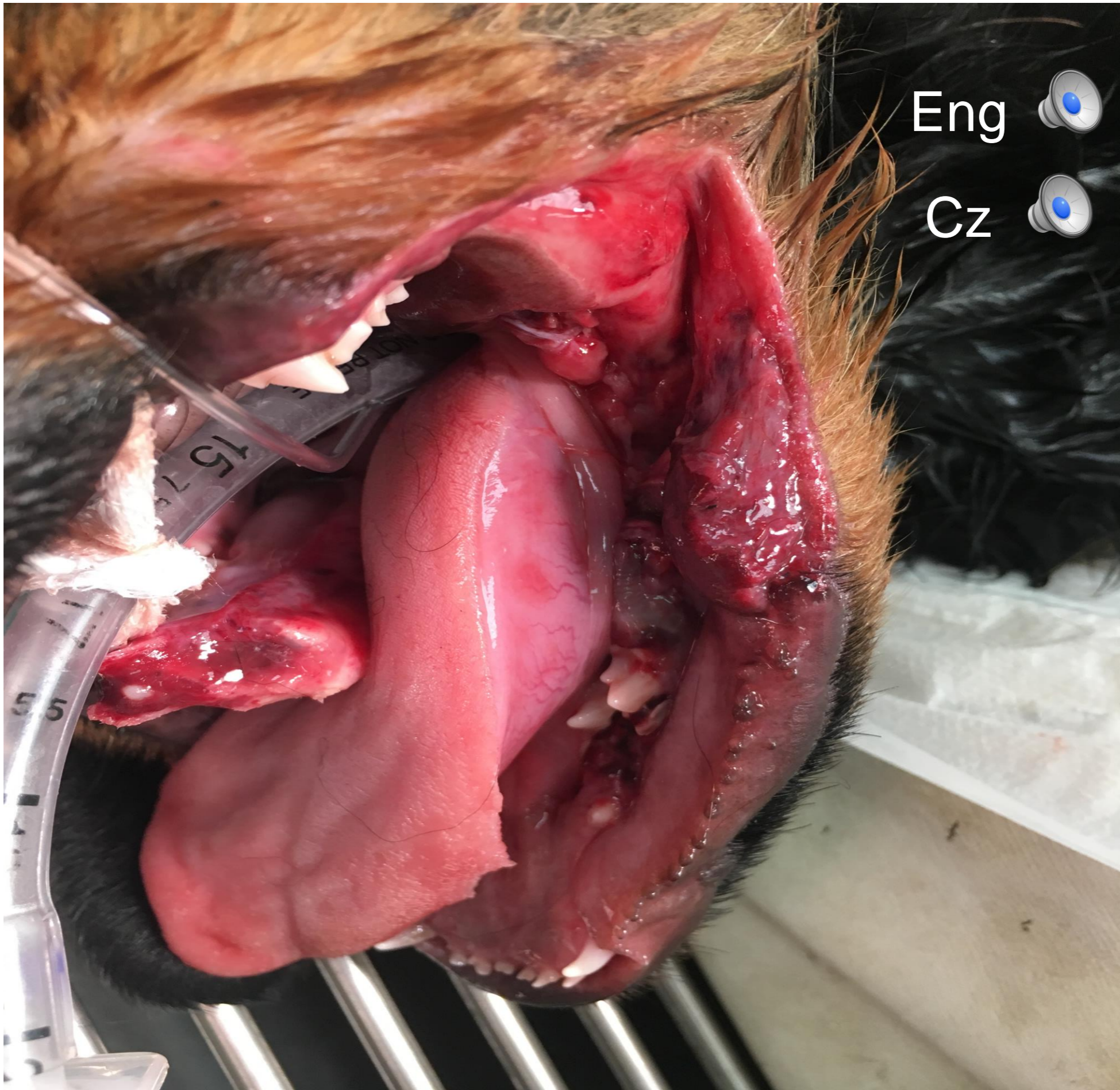

Eng



Cz



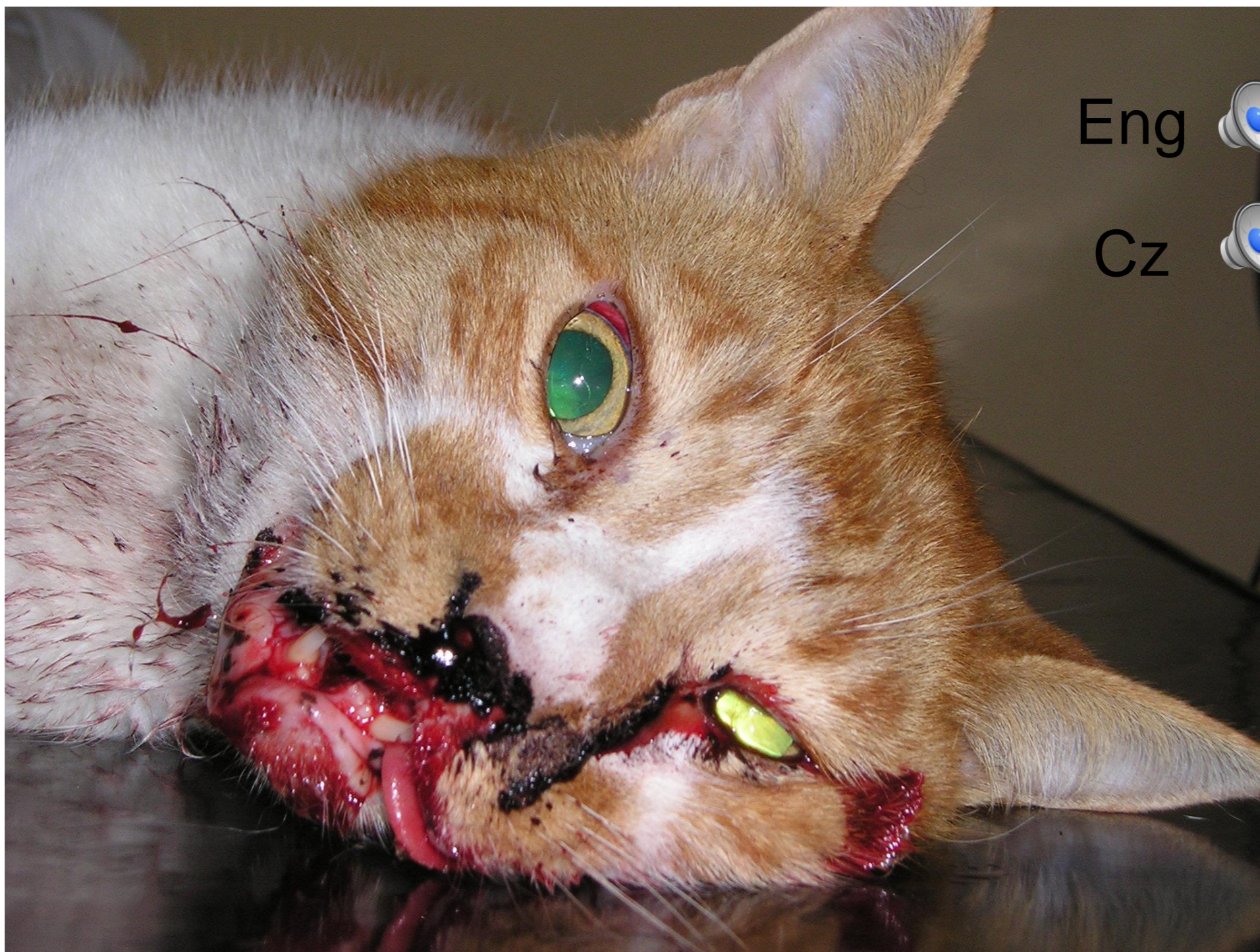

Eng



Cz



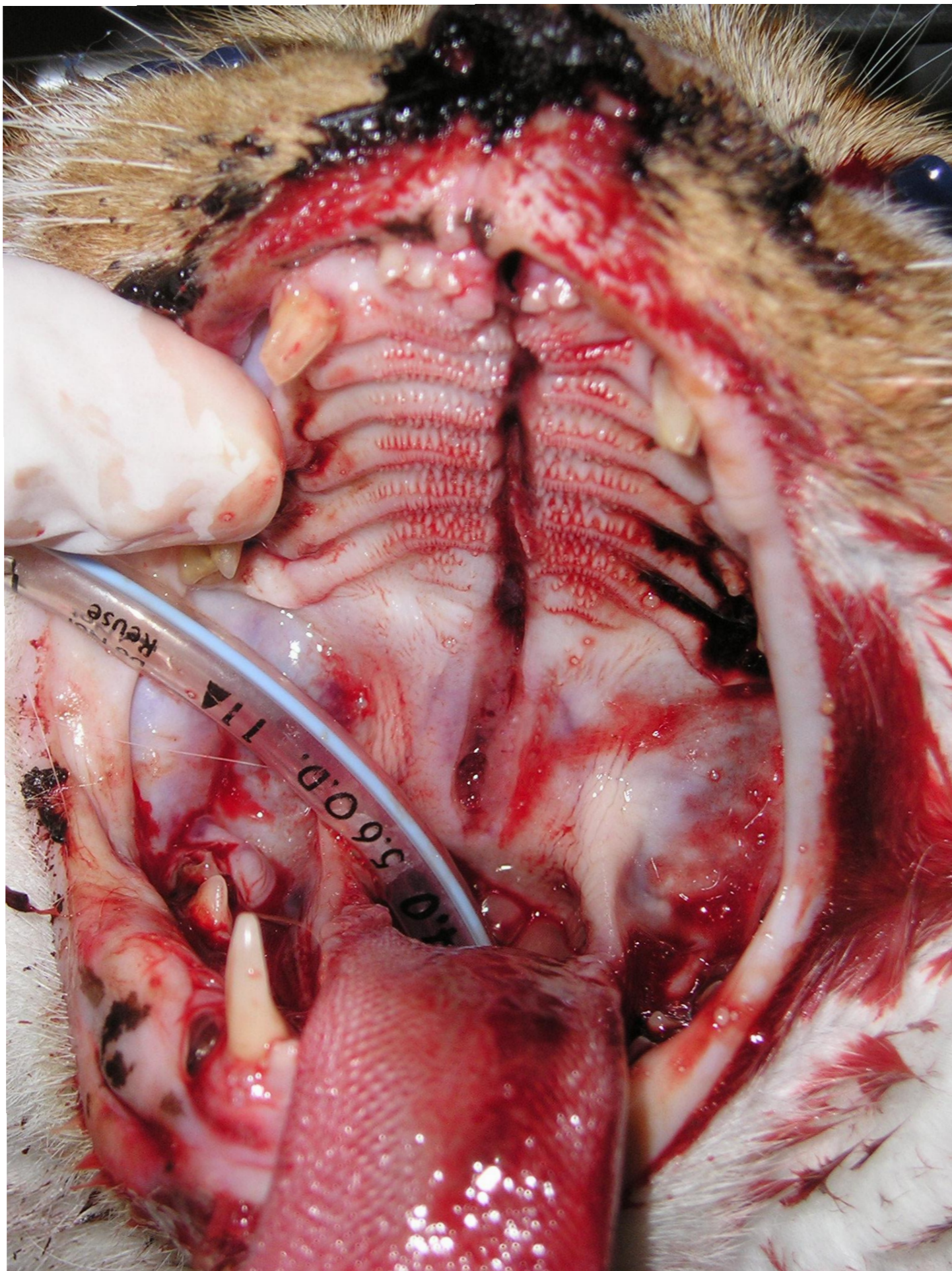


Eng



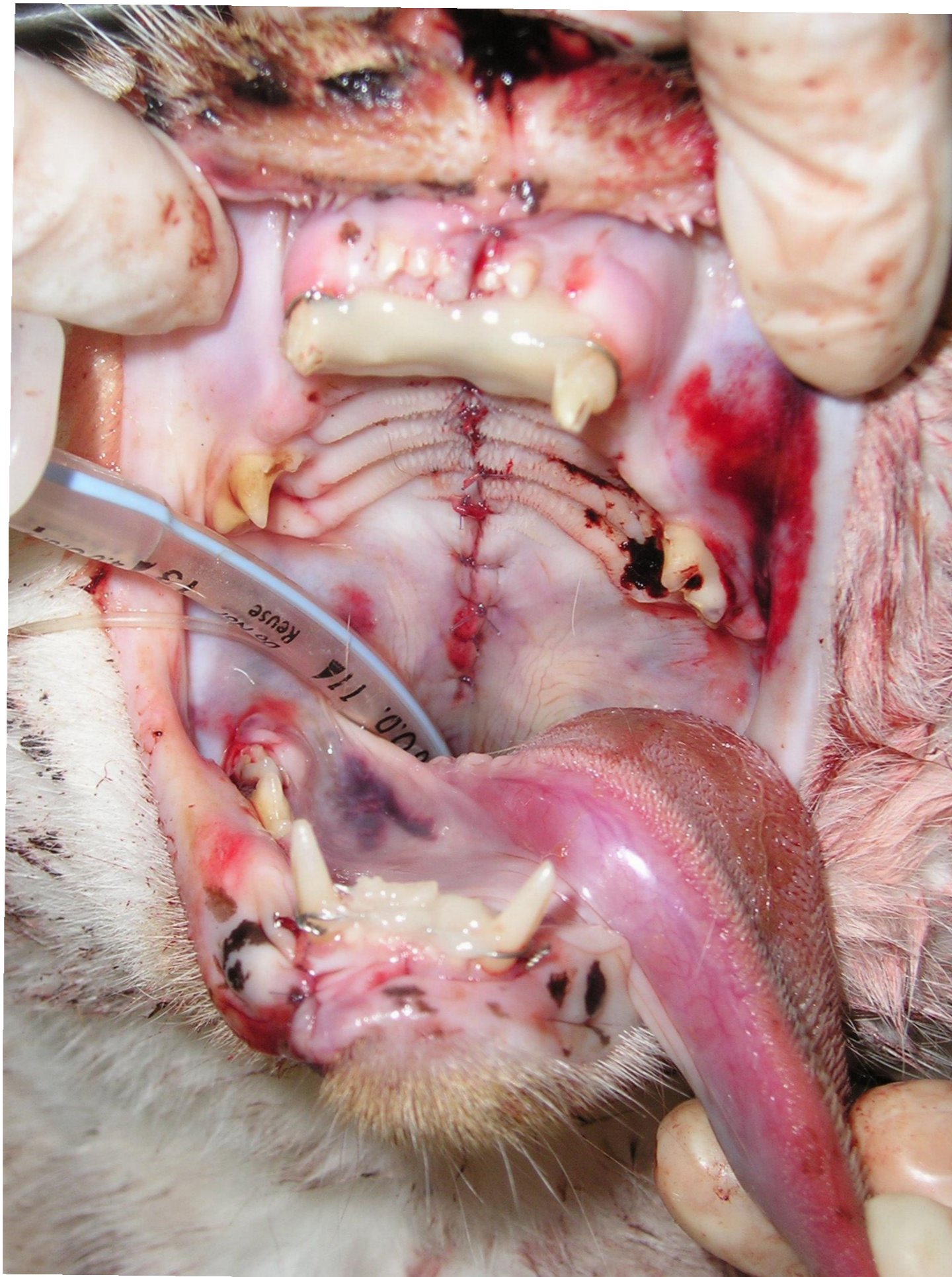
Cz





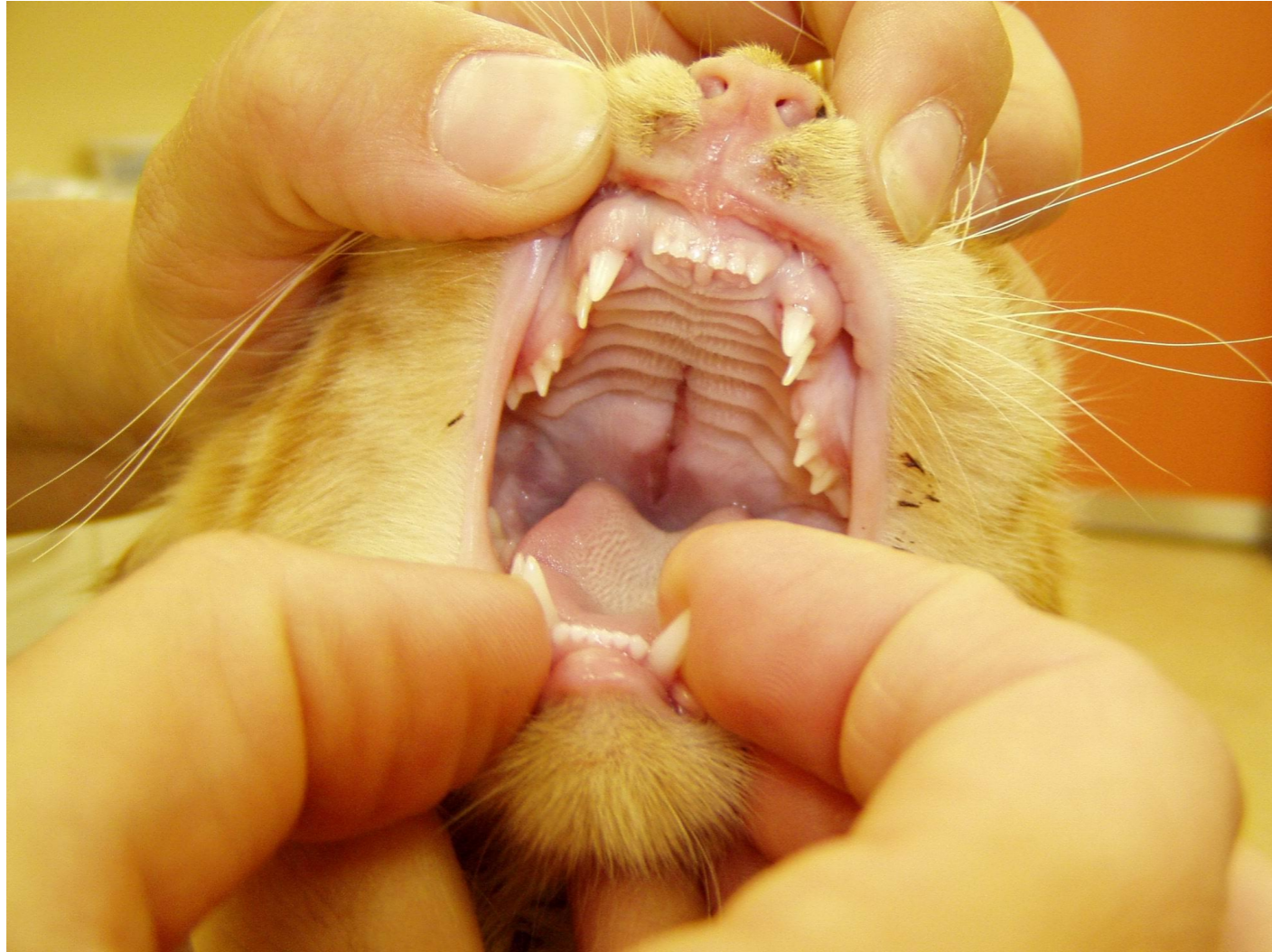
Eng 

Cz 



Eng 

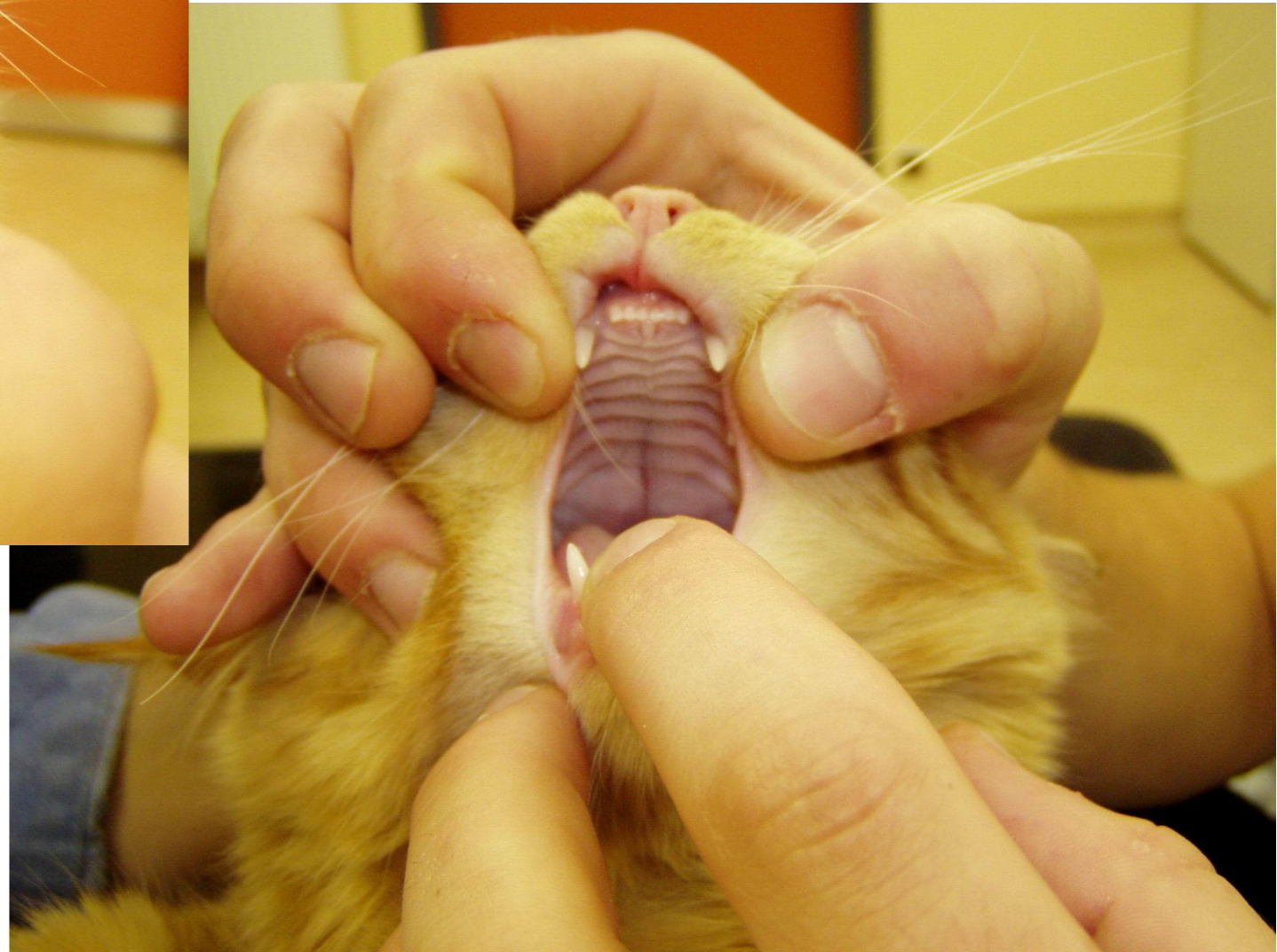
Cz 

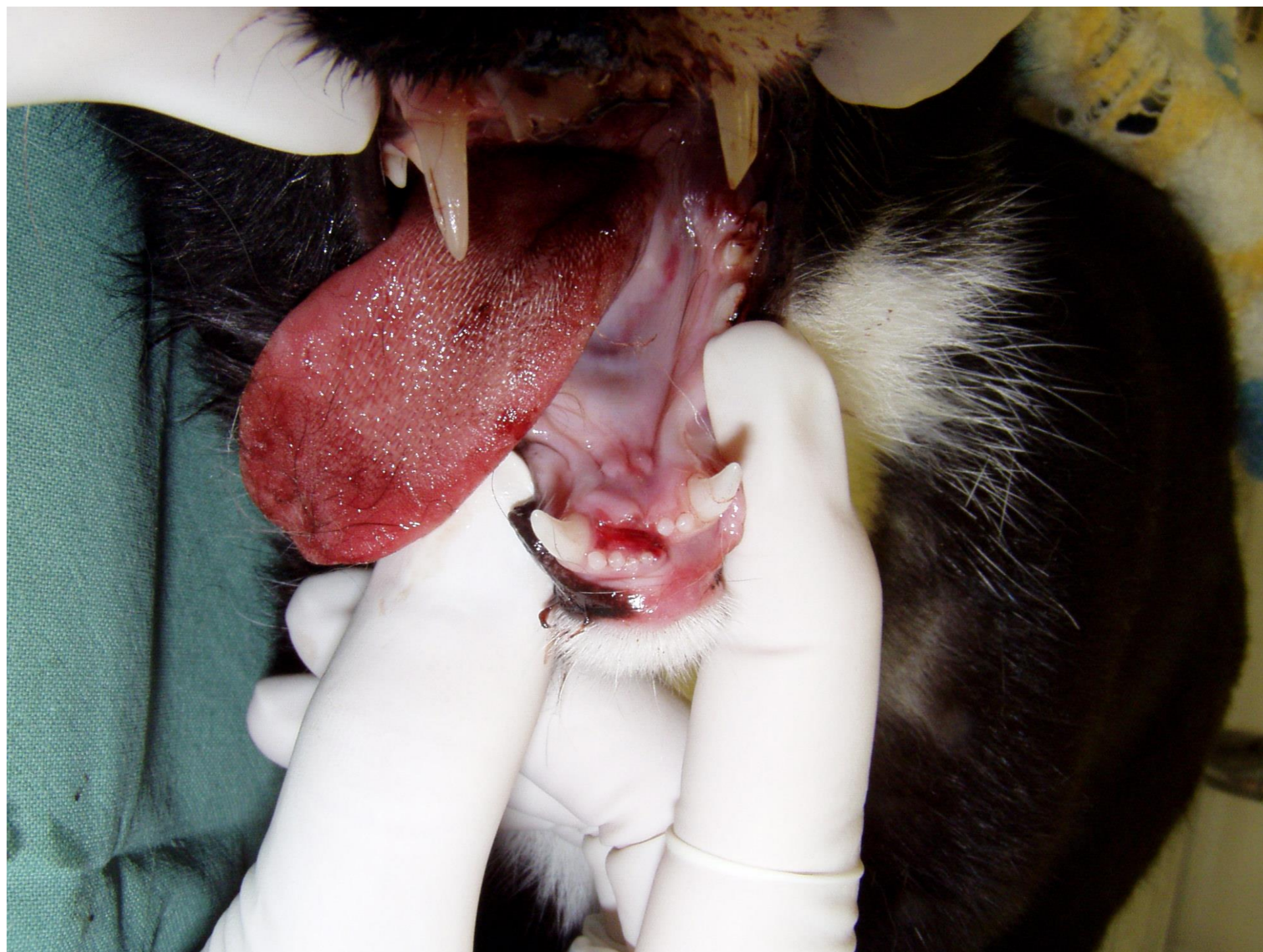

Cz



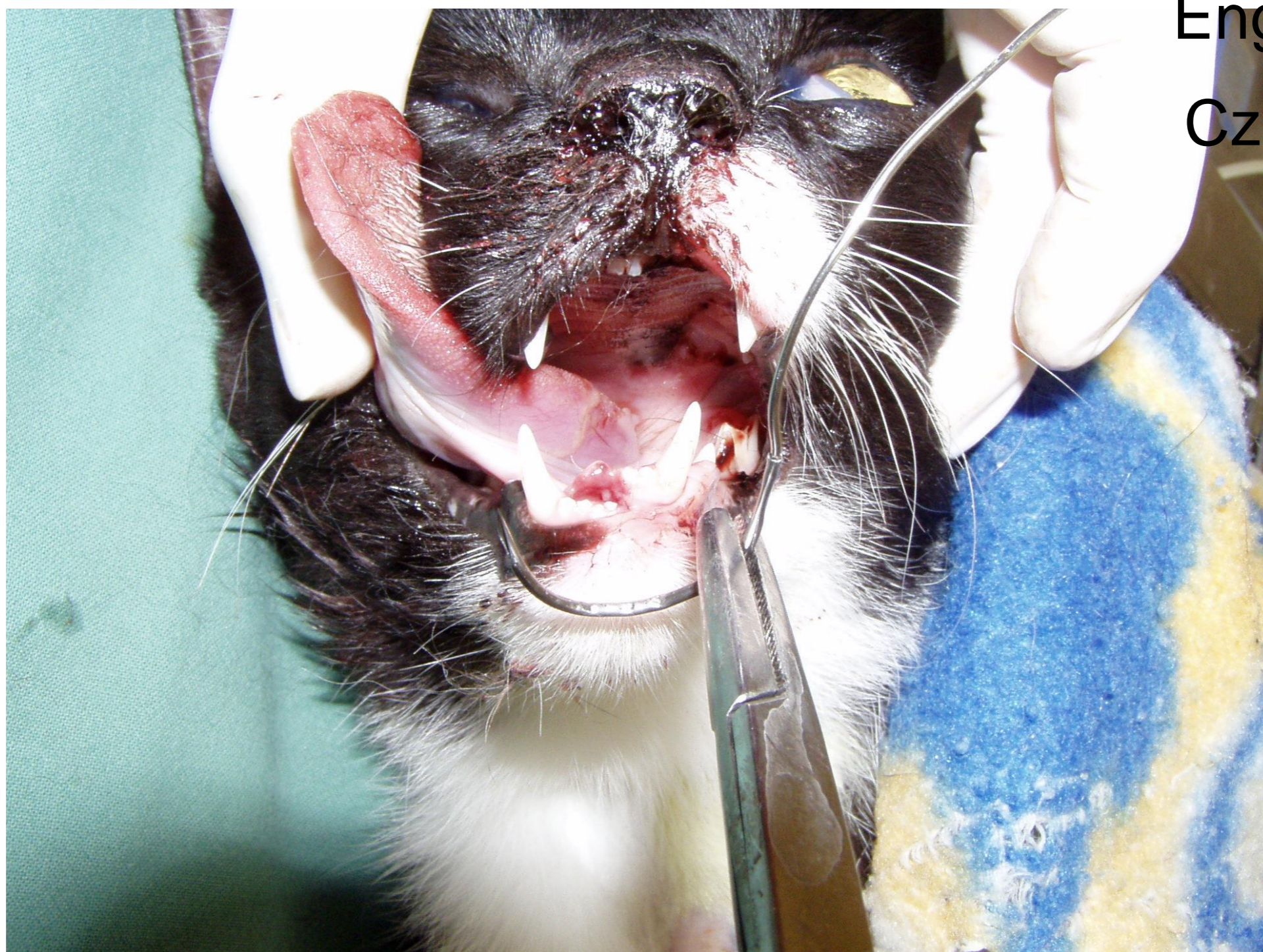Eng





Eng 

Cz 



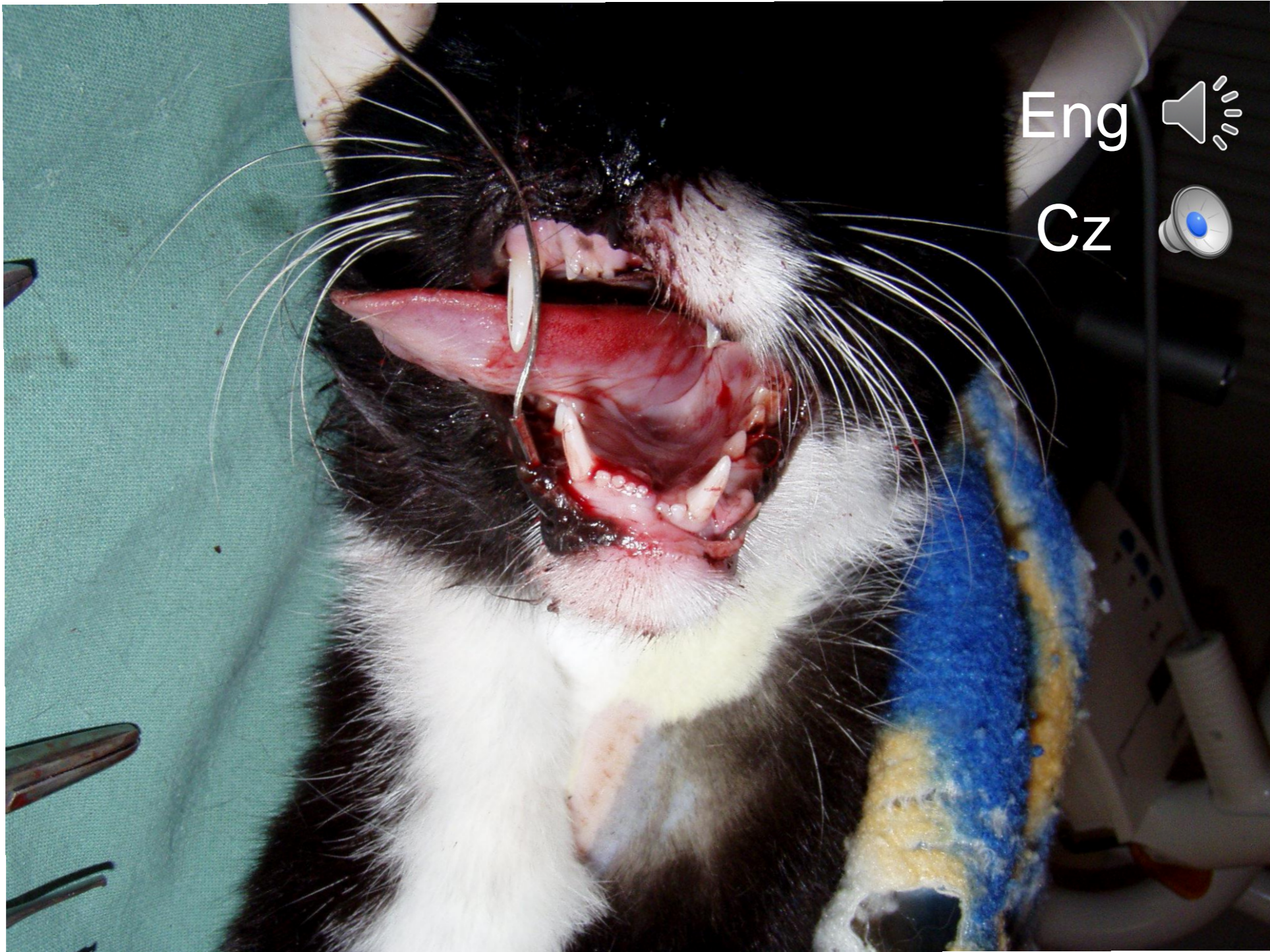Eng



Cz





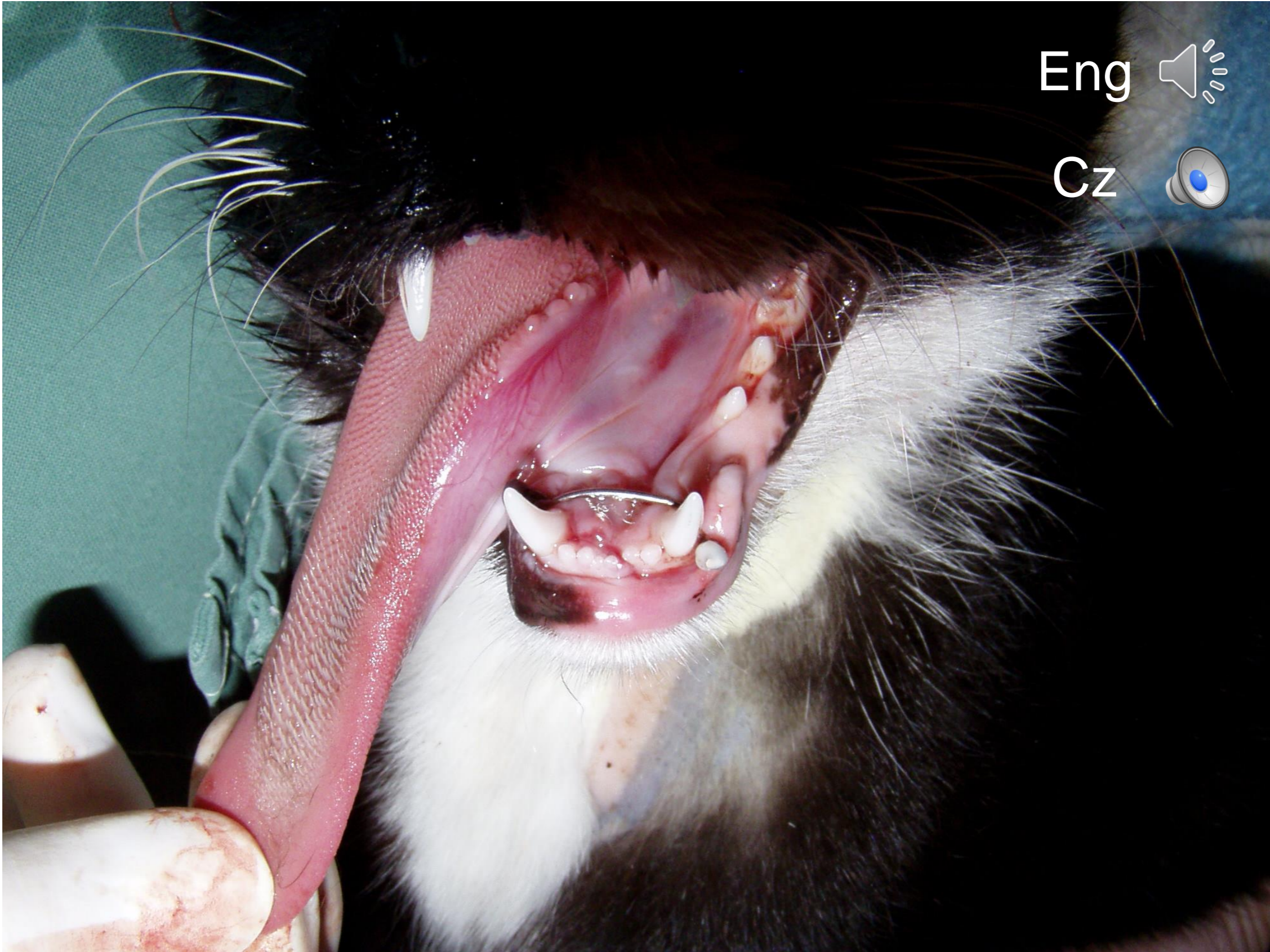

Eng



Cz





Eng



Cz





Eng



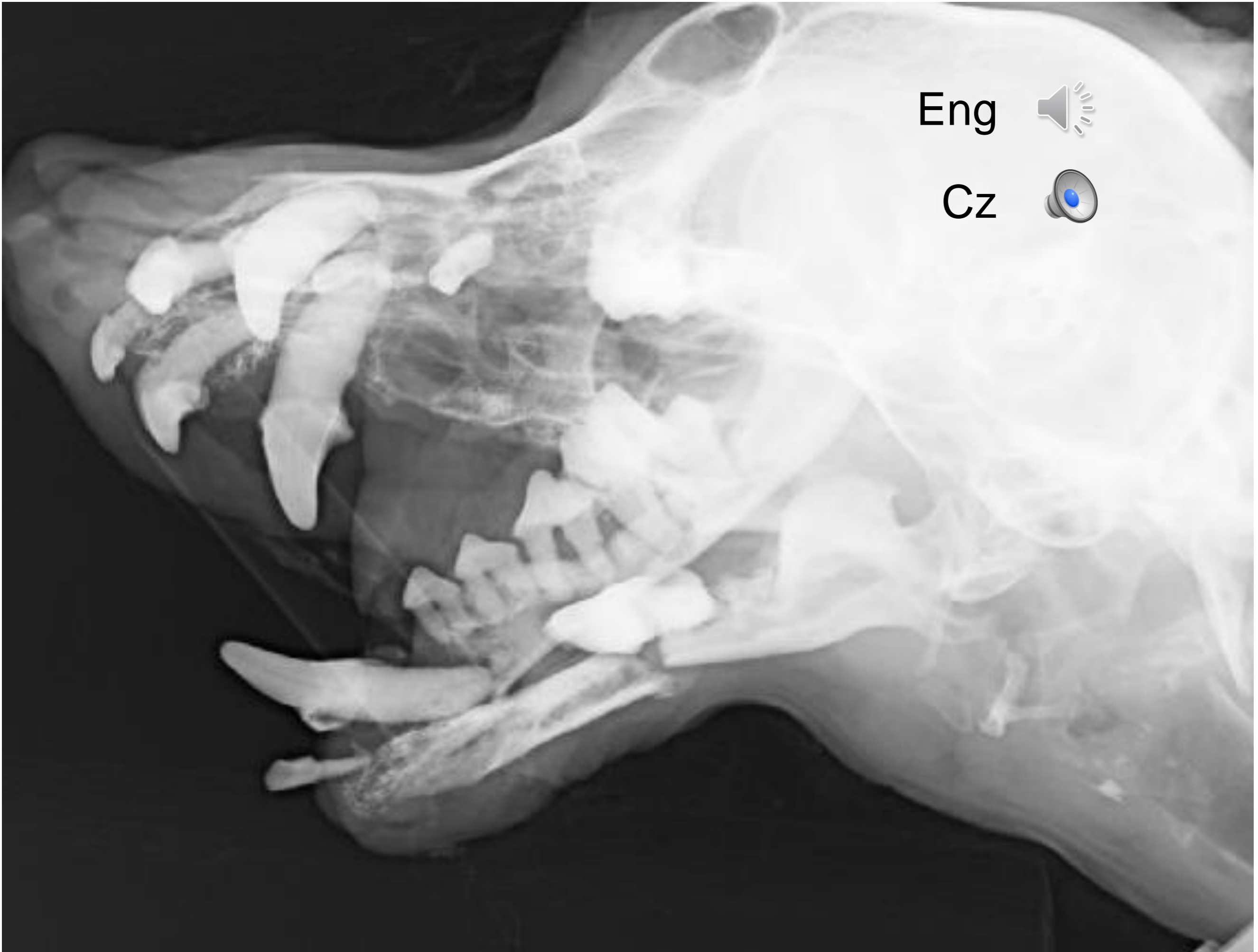
Cz

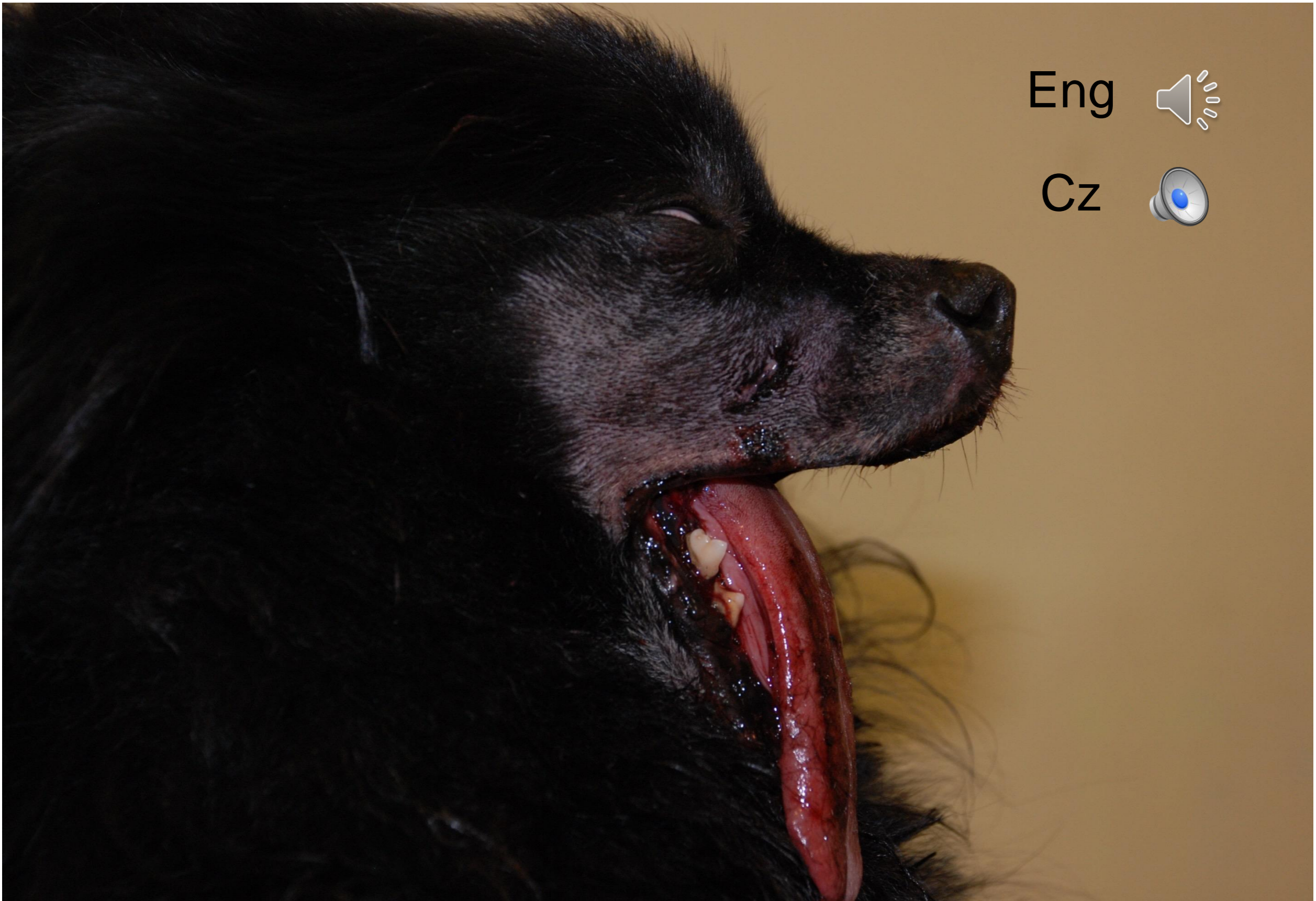

Eng



Cz



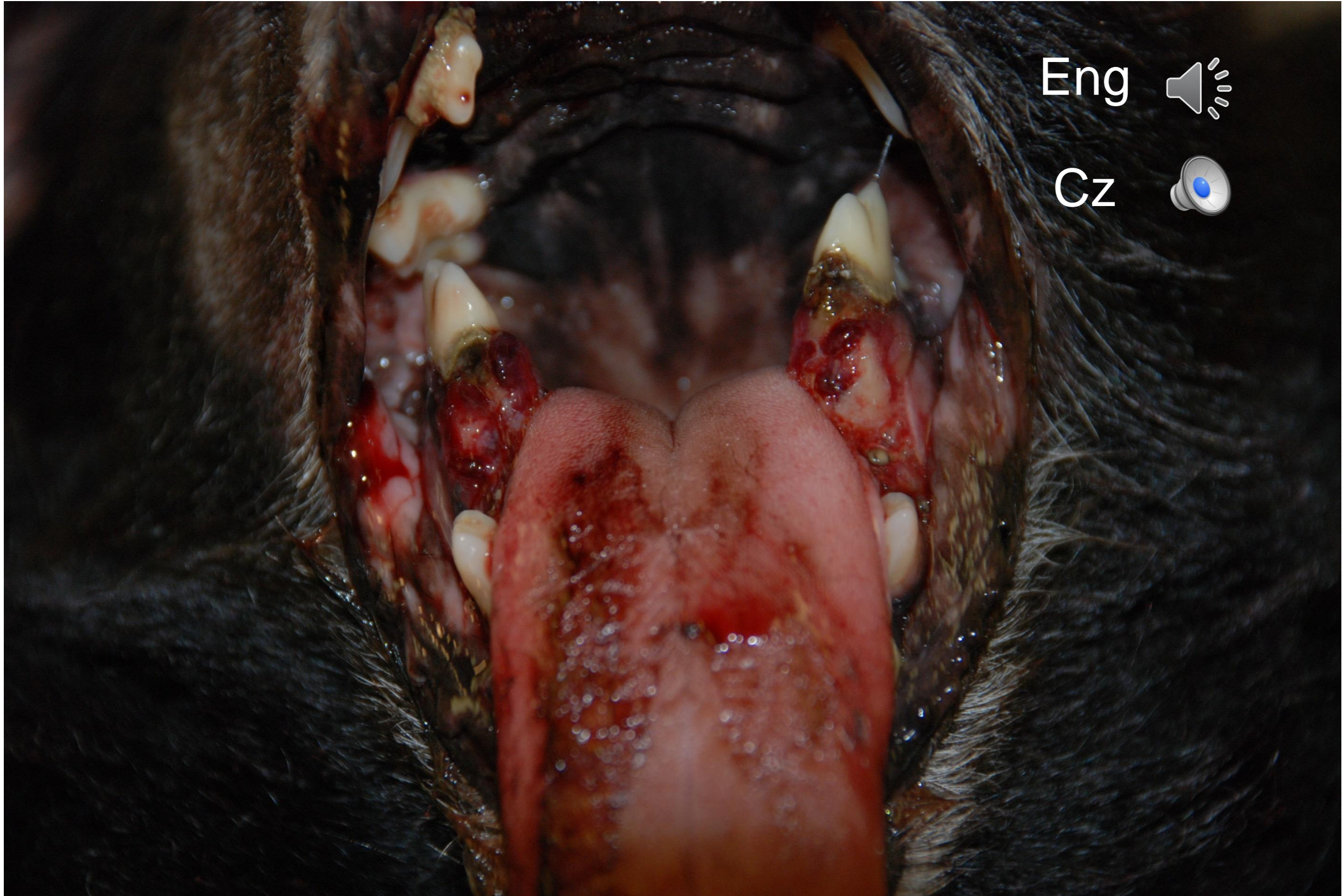

Eng



Cz



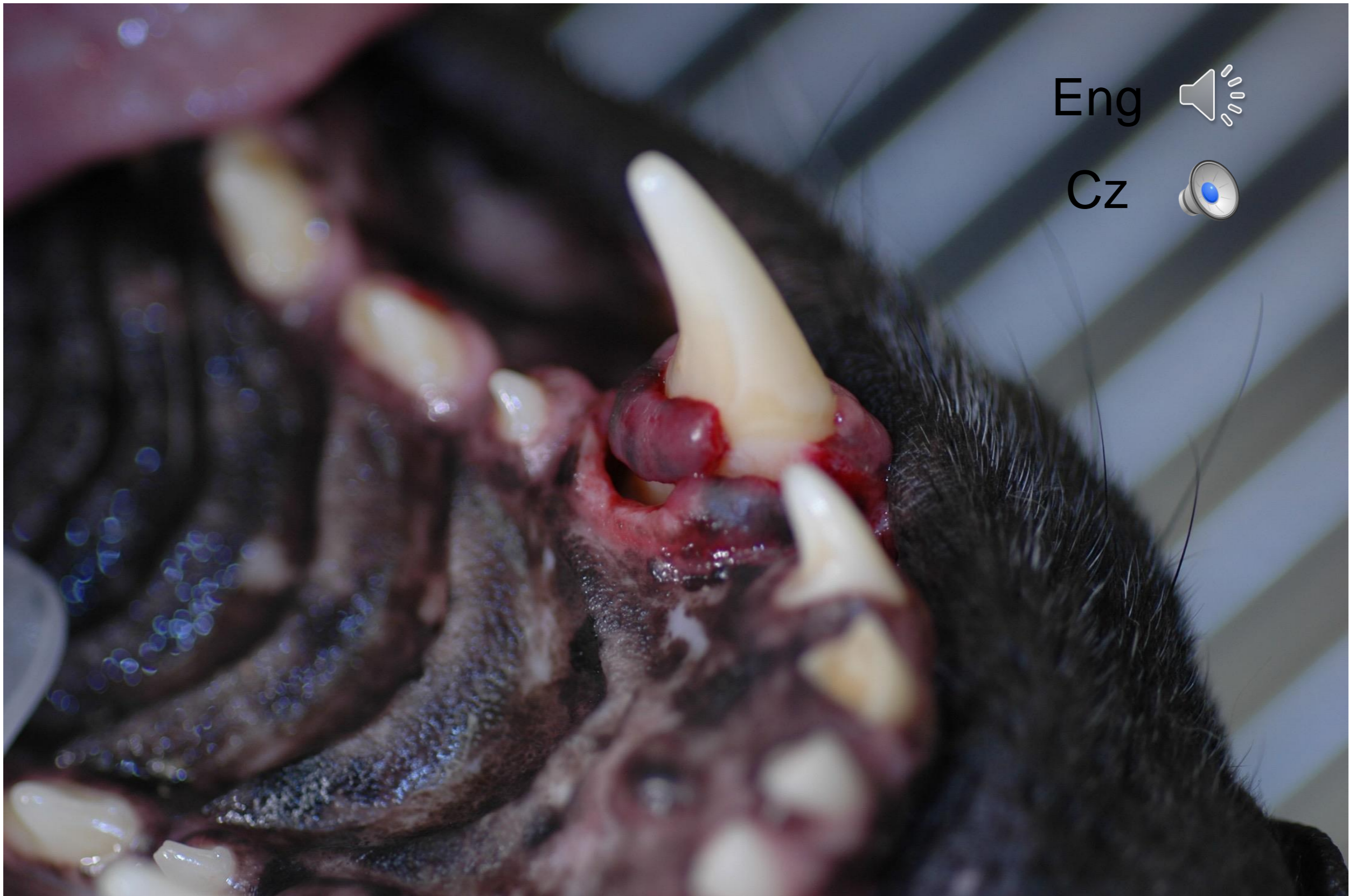

Eng



Cz



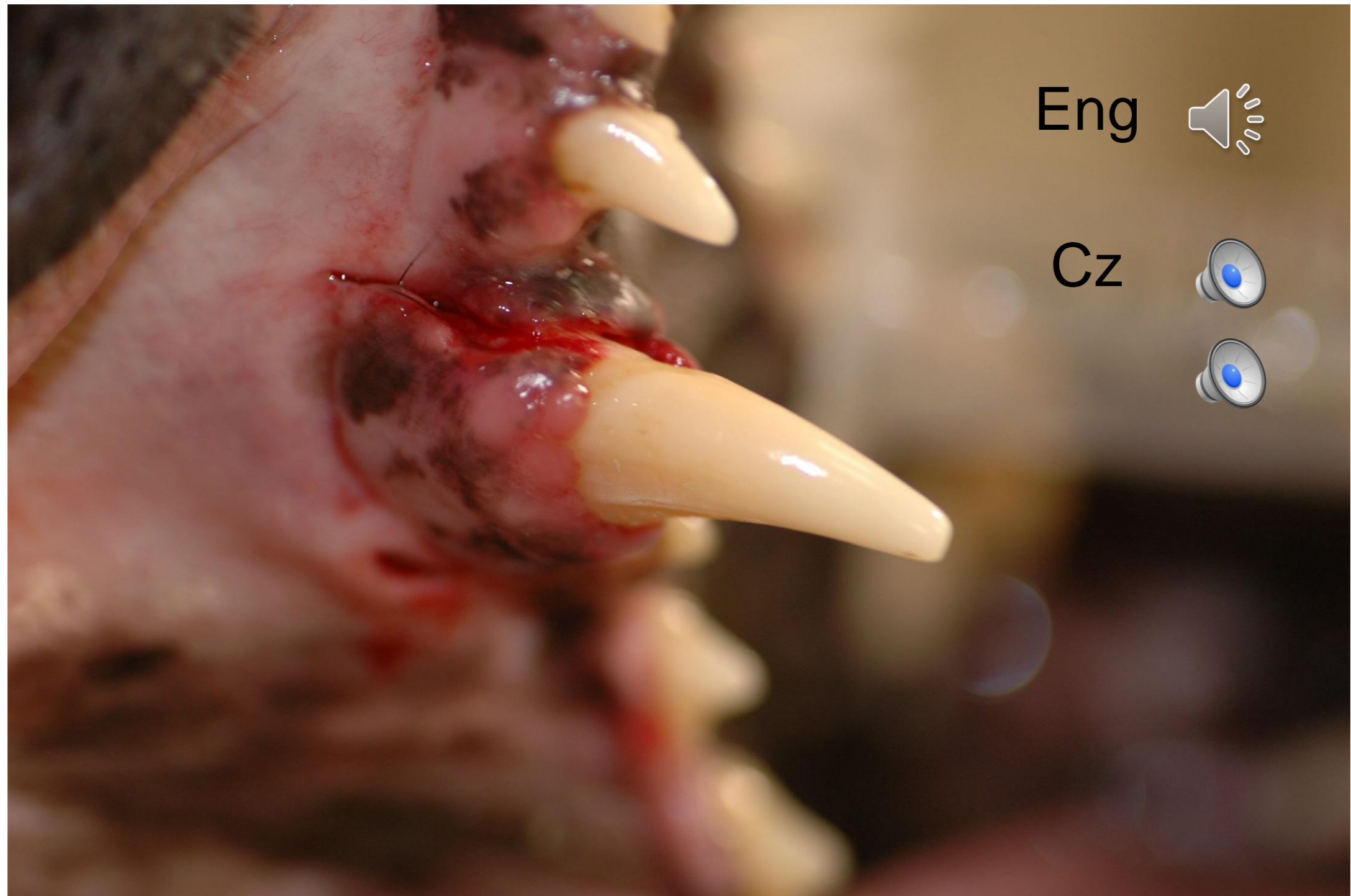

Eng

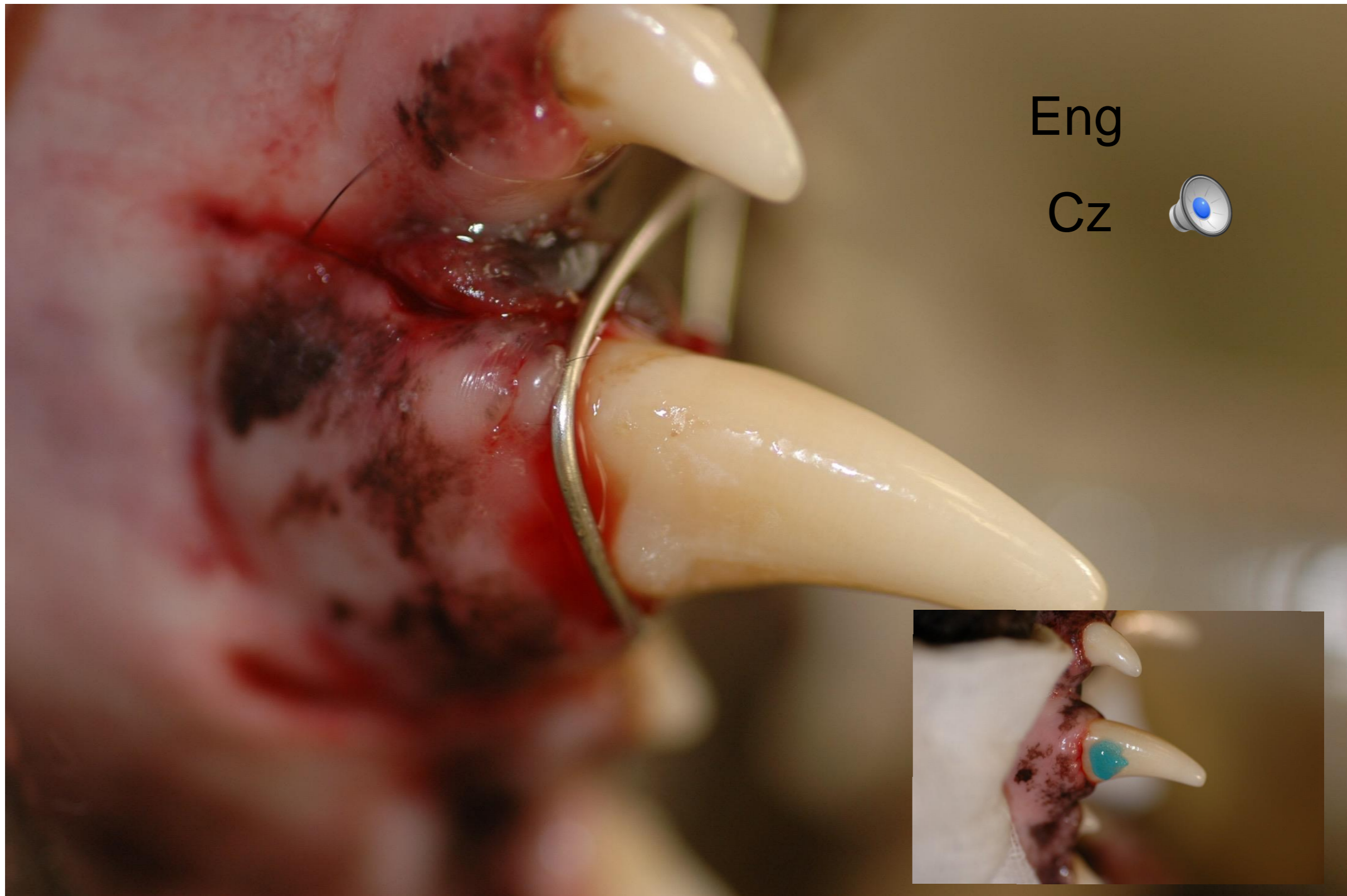


Cz









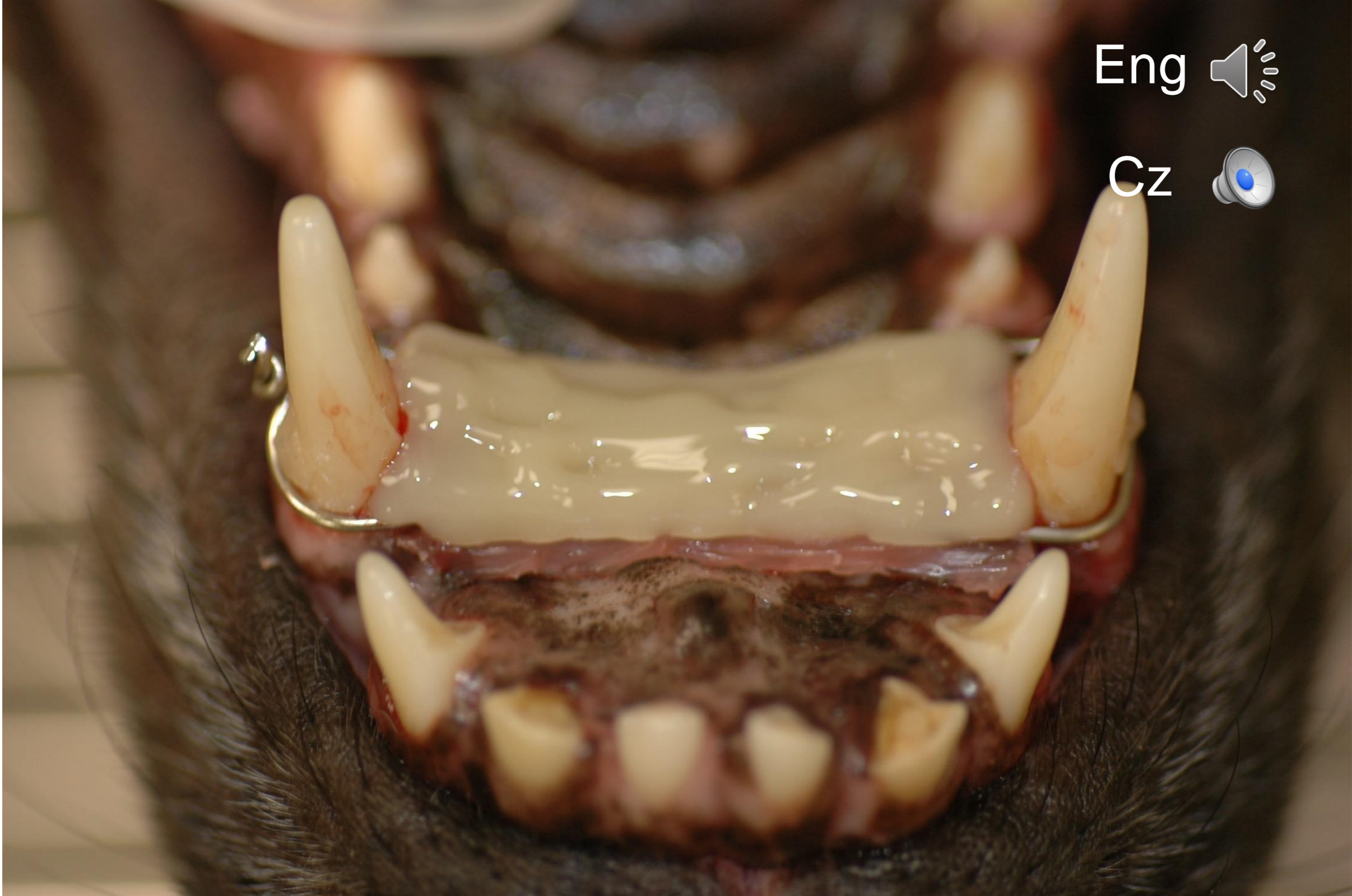Eng

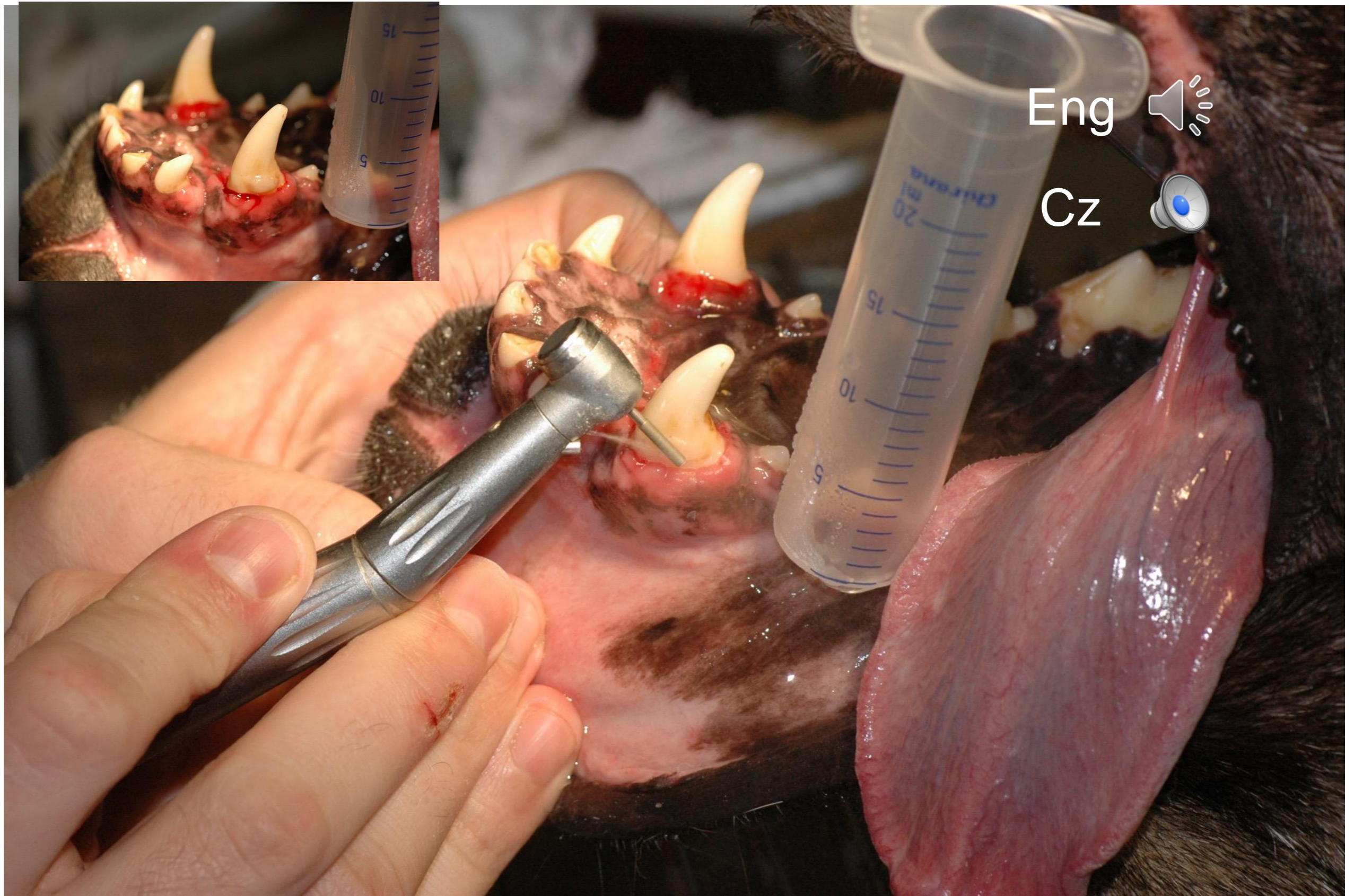
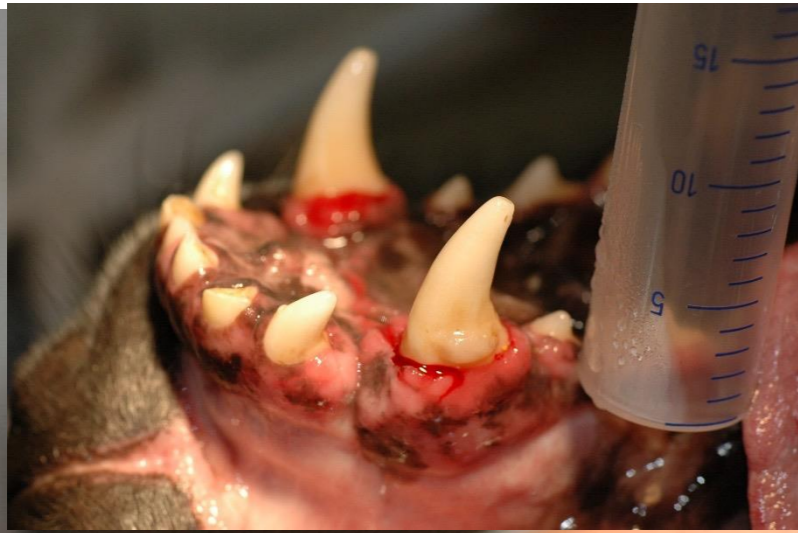Cz



Eng 

Cz 





Eng



Cz

